

Received: 2025.10.03

Accepted: 2026.04.29




Available online: 2026.05.20

Published: 2026.XX.XX

An 18-Year-Old Man with Bleeding From a Meckel's Diverticulum of the Terminal Ileum Diagnosed by 99mTc-Pertechnetate Scintigraphy (Meckel's Scan)

Authors' Contribution:

Study Design A
Data Collection B
Statistical Analysis C
Data Interpretation D
Manuscript Preparation E
Literature Search F
Funds Collection G

ABCDEFG 1 **Hasan M. Alswiket** 
ABCDEFG 2 **Rakan S. Alshahrani** 
ABCDEFG 3 **Ibrahim M. Alzahrani**
ABCDEFG 1 **Mosab A. Alarfaj** 

1 Department of Surgery, King Fahd Hospital of the University, Imam Abdulrahman Bin Faisal University, Al-Khobar, Saudi Arabia
2 Department of Urology, King Fahd Hospital of the University, Imam Abdulrahman Bin Faisal University, Al-Khobar, Saudi Arabia
3 Department of Medicine, King Fahd Hospital of the University, Imam Abdulrahman Bin Faisal University, Dammam, Saudi Arabia

Corresponding Author: Hasan M. Alswiket, King Faisal Ibn Abd Al Aziz St, 34224, Dammam, Saudi Arabia, Phopne: +966576609368, e-mail: hshs2009hs@hotmail.com
Financial support: None declared
Conflict of interest: None declared

Patient: Male, 18-year-old
Final Diagnosis: Meckel's diverticulum
Symptoms: Abdominal pain • gastrointesinal haemorrhage
Clinical Procedure: —
Specialty: Surgery

Objective: Unusual clinical course


Background: Meckel's diverticulum represents the most common congenital anomaly of the gastrointestinal tract in the pediatric population. Although it is rarely symptomatic, painless rectal bleeding is the most common manifestation among pediatric patients. In contrast, Meckel's diverticulum is considerably rare in adults, in whom intestinal obstruction and diverticulitis are more frequent complications than bleeding. When it is suspected, a Meckel's scan is the most sensitive and specific diagnostic tool. Surgical excision remains the treatment of choice for Meckel's diverticulum. This report describes the case of an 18-year-old man with bleeding from a Meckel's diverticulum of the terminal ileum diagnosed by 99mTc-pertechnetate scintigraphy (Meckel's scan).

Case Report: We report the case of an 18-year-old male patient who presented to the emergency department with a 24-hour history of 4 episodes of fresh rectal bleeding, associated with dizziness, nausea, palpitations, and a loss of consciousness. The patient underwent an extensive diagnostic workup, including computed tomography scan, sigmoidoscopy, colonoscopy, esophagogastroduodenoscopy, and capsule endoscopy, none of which revealed any abnormalities. A Meckel's scan eventually confirmed the presence of a Meckel's diverticulum on day 4 of admission, followed by a successful laparoscopic segmental resection on day 10 of admission.

Conclusions: Meckel's diverticulum, a common etiology of lower gastrointestinal bleeding in pediatric patients, presents a diagnostic challenge in adults, requiring a heightened index of suspicion. Clinical suspicion should be raised in cases with inconclusive initial investigations, particularly in younger adults.

Keywords: Diverticulum • Endoscopy, Gastrointestinal • Gastrointestinal Hemorrhage • Laparoscopy

Full-text PDF: <https://www.amjcaserep.com/abstract/index/idArt/951726>

 2819

 1

 2

 31



Publisher's note: All claims expressed in this article are solely those of the authors and do not necessarily represent those of their affiliated organizations, or those of the publisher, the editors and the reviewers. Any product that may be evaluated in this article, or claim that may be made by its manufacturer, is not guaranteed or endorsed by the publisher

Introduction

Meckel's diverticulum affects only 2% of the population and is rarely symptomatic, particularly in adults. While lower gastrointestinal (GI) bleeding is the most common manifestation in pediatric patients, intestinal obstruction and diverticulitis emerge as more frequent complications in adults, in whom bleeding is relatively rare. Due to its rarity in adults, Meckel's diverticulum poses a diagnostic challenge, often leading to misdiagnosis preoperatively [1].

When the omphalomesenteric duct fails to undergo complete obliteration during embryonic development, a diverticulum forms in the small intestine along the antimesenteric side of the ileum, approximately 2 feet proximal to the ileocecal valve, known as Meckel's diverticulum [2,3]. This congenital anomaly is the most common GI tract anomaly, occurring in approximately 2% of infants. Meckel's diverticulum predominantly affects the pediatric population, particularly those under 2 years old, and is rarely encountered in adults [2].

Although it is often asymptomatic, approximately 2% of patients with Meckel's diverticulum will exhibit symptoms. When symptomatic, patients typically present with painless lower GI bleeding or various abdominal symptoms during their first decade of life [2]. The bleeding, originating from the small intestine downstream from the diverticulum, results from acid secretion by ectopic gastric mucosa within the diverticulum [4]. Lower GI bleeding often manifests as "currant jelly"-colored stool [5]. Additionally, Meckel's diverticulum can present with intestinal obstruction due to intussusception, inversion, torsion, herniation, volvulus, or inflammatory processes [6]. Patients with intestinal obstruction typically exhibit abdominal pain, distension, nausea, and vomiting. Meckel's diverticulitis, which is the acute inflammation of the diverticulum, can also complicate Meckel's diverticulum, presenting with abdominal pain, tenderness, distension, and symptoms of peritoneal irritation in cases of perforation [7].

Diagnosing Meckel's diverticulum in pediatric patients under 2 years old with painless rectal bleeding is relatively straightforward, as it accounts for approximately 50% of lower GI bleeding cases in this age group [5]. In such cases, a Meckel's scan, a nuclear study utilizing technetium-99m to visualize the diverticulum, is the most sensitive diagnostic test [8]. In cases of active bleeding, tagged red blood cell scans, angiograms, double-balloon enteroscopy, and capsule endoscopy can be helpful in localizing the bleeding source, but are typically reserved for when the Meckel's scan is inconclusive. Diagnostic laparoscopy or laparotomy remains a last resort for hemodynamically unstable patients or when radiological investigations are inconclusive [8,9].

Surgical intervention is indicated for symptomatic patients, with surgical excision being the treatment of choice. This can be performed laparoscopically or via an open technique, using simple diverticulectomy or segmental resection. The management of asymptomatic, incidentally diagnosed Meckel's diverticulum remains unclear, although many surgeons advocate for resection [10].

We present a case of an 18-year-old male patient who presented with severe lower GI bleeding due to Meckel's diverticulum, necessitating multiple blood transfusions and intensive care unit (ICU) admission. The case highlights the diagnostic pathway, with the Meckel's scan serving as the key turning point, and underscores the importance of maintaining a high index of suspicion for timely diagnosis in adults.

Case Report

We report a case of an 18-year-old male patient with no prior medical history, who presented to the emergency department with a chief concern of 4 episodes of fresh rectal bleeding within the past 24 hours. The bleeding episodes, initially mixed with stool, began approximately 1 month prior to presentation. Associated symptoms included dizziness, nausea, palpitations, and a brief loss of consciousness lasting 2 minutes, from which the patient spontaneously regained consciousness. Notably, the patient denied experiencing hematemesis, constipation, diarrhea, skin rash, or ulcers. He had no significant risk factors for lower GI bleeding, being medically free, with no history of GI disease, bleeding disorders, recent infection, medication use including NSAIDs or anticoagulants, trauma, or family history of GI disorders. Upon physical examination, he had stable vital signs and no fever. Abdominal examination revealed a soft, lax abdomen without guarding, rigidity, distension, or organomegaly. Digital rectal examination revealed brown-colored blood staining on the glove. Proctoscopic examination did not show any abnormal findings. Laboratory test results showed a hemoglobin level of 11.4 g/dL, a white blood cell count of $9.4 \times 10^9/L$, and a platelet count of $352 \times 10^9/L$. An abdominal computed tomography (CT) scan with contrast was conducted and did not reveal any significant abnormalities.

Before presenting to our hospital, the patient had multiple hospital visits due to recurrent per rectal bleeding over the past month. Initially, he was admitted to the ICU due to severe lower GI bleeding, which resulted in a remarkable drop in hemoglobin to 8 g/dL, prompting blood transfusion. Subsequently, the patient underwent 6 colonoscopies in an attempt to identify and control the source of bleeding. During one of these procedures, a 2-mm rectal laceration was identified and treated with clipping. However, bleeding recurred, and additional hemoclips were applied approximately 1 month prior to the

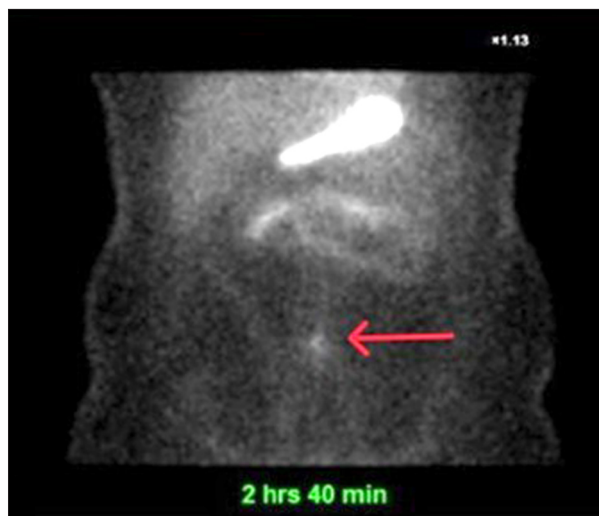


Figure 1. Meckel's scan showing low-grade focal activity (red arrow) in the midline abdomen at the level of aortic bifurcation, which persisted for 2 hours and 40 minutes, indicating the presence of ectopic gastric mucosa compatible with Meckel's diverticulum.

current presentation. Since then, a rectal Dieulafoy lesion was suspected as a possible source of GI bleeding.

During the current emergency department visit, following comprehensive investigations and resuscitation with intravenous fluids, the patient underwent emergency sigmoidoscopy. The procedure revealed a rectum full of clots, which was cleaned using water irrigation; no active bleeding was observed, and the 2 previously applied clips were noted in the rectum. Subsequently, the patient was admitted and scheduled for colonoscopy and esophagogastroduodenoscopy (EGD) the following day, with ongoing monitoring of vital signs, hemoglobin levels, and coagulation profile. However, he experienced recurrence of bleeding in the ward, resulting in approximately 100 mL of fresh blood collected in the diaper, which stopped spontaneously.

During the second day of admission, the patient's vital signs remained stable, despite mild tachycardia, while he received IV fluid Ringer's lactate at 145 mL/h and pantoprazole infusion at 8 mg/h. His hemoglobin level dropped to 8.4 g/dL. Colonoscopy revealed old clots and blood accumulation in the rectum, with ulcers observed around the previously applied clips; 2 additional clips were placed over the ulcers. As the scope was advanced, old blood was seen in the colon and ileum, but the source of bleeding was not identified. In the same session, EGD and capsule endoscopy were performed, which also failed to identify the cause of GI bleeding.

The patient was kept under observation for further investigations to identify the source of lower GI bleeding. Despite

initial efforts, the patient's hemoglobin level continued to drop, from 8.4 g/dL before the colonoscopy to 7.1 g/dL the day after the procedure. This necessitated the transfusion of 3 units of packed red blood cells, which increased the patient's hemoglobin level to 8.5 g/dL. Although Meckel's diverticulum is an uncommon cause of lower GI bleeding in adult patients, a Meckel's scan was ordered on day 4 of admission, given the failure of previous investigations to identify the bleeding source. Fortunately, Meckel's scan provided the diagnosis, revealing a low-grade, small, ill-defined focal activity in the midline anterior abdomen at the level of the aortic bifurcation, left paracentral plane, which remained persistent after 2 hours and 40 minutes (Figure 1). The findings of the Meckel's scan, combined with the patient's clinical presentation, were consistent with Meckel's diverticulum as the source of lower GI bleeding.

Following the blood transfusion, the patient's hemoglobin level remained above 8 g/dL, and he was scheduled for emergency laparoscopic segmental intestinal resection. The procedure was performed on day 10 of admission. Initially, pneumoperitoneum was established using the Veress needle, followed by the placement of one 10-mm and three 5-mm trocars for optimal access. Diagnostic laparoscopy revealed the Meckel's diverticulum, located approximately 2.3 cm proximal to the ileocecal valve along the antimesenteric side of the ileum. The diverticulum was actively bleeding, with a mesenteric attachment, but showed no signs of inflammation. After mobilizing the small intestine and exposing the base of the diverticulum, a segmental resection of the ileum containing the diverticulum was performed using a linear stapler, ensuring a clear margin of healthy tissue (Figure 2). Upon removal of the diverticulum, a mesenteric defect was noted at its base, which was closed using absorbable sutures in a running fashion to prevent internal herniation. The resected specimen was sent to pathology, which revealed a Meckel's diverticulum containing ectopic oxyntic-type gastric mucosa with chronic inactive inflammation and no evidence of dysplasia or malignancy.

On postoperative day 1, the patient's vital signs remained stable, and he had no symptoms except mild port site pain. Notably, he did not experience any further lower GI bleeding, and his abdomen was soft and lax. His hemoglobin level remained stable at 8.6 g/dL. By postoperative day 4, the patient was ambulating well, tolerating a full liquid diet, and passing stool and urine without issue. The patient was stable for discharge at this time. He was discharged on paracetamol and pantoprazole, with a scheduled outpatient follow-up appointment in 2 weeks. At the follow-up visit, he reported no more episodes of per rectal bleeding and was tolerating a full regular diet. The patient was scheduled for a subsequent visit in 6 months.

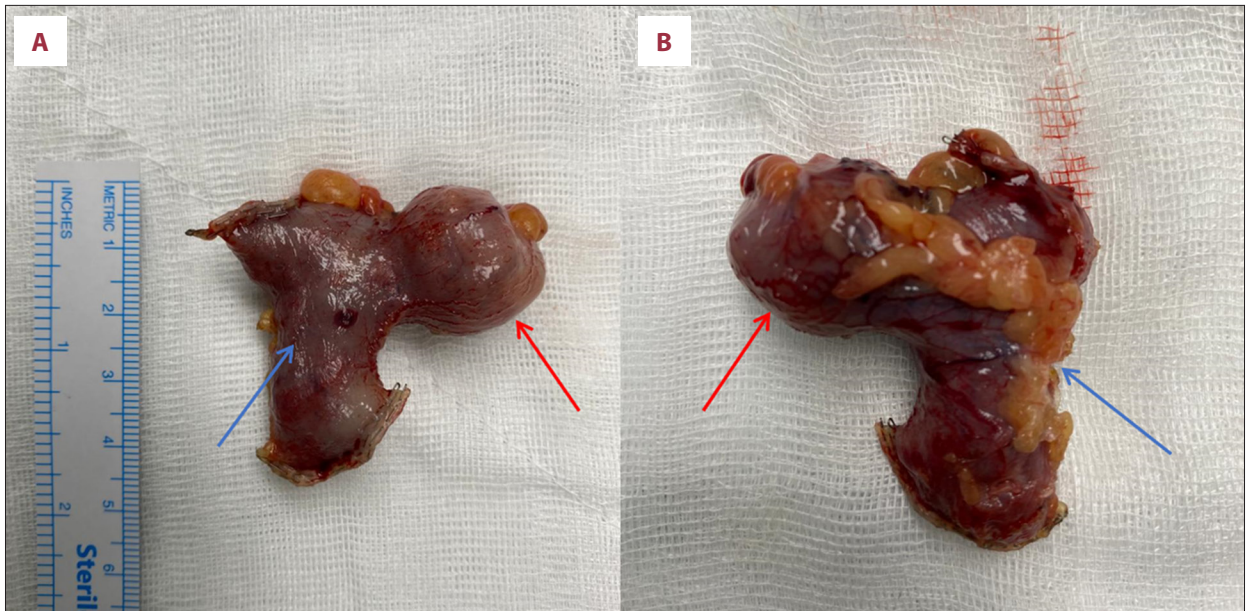

Figure 2. Resected specimen of Meckel's diverticulum obtained following segmental ileum resection from the antimesenteric (A) and mesenteric (B) sides. The specimen consists of the diverticulum (red arrows; measuring 2.5 cm in height and 2.3 cm in width) attached to a segment of the resected ileum (blue arrows).

Discussion

This case highlights the importance of considering bleeding from a Meckel's diverticulum of the terminal ileum in adult patients with unexplained GI bleeding and the diagnostic value of the Meckel's scan. It describes the case of an 18-year-old who arrived at the emergency department with severe, acute lower GI bleeding. Symptoms included hematochezia, dizziness, nausea, palpitations, and a brief loss of consciousness. The patient had experienced several prior episodes of bleeding, some of which necessitated ICU care and blood transfusions. Lower GI bleeding carries a considerable risk, with mortality rates reported between 4% and 10% [11]. Hence, immediate evaluation and stabilization are critical and should take precedence over diagnostic testing in these urgent situations [12].

Lower GI bleeding typically presents as hematochezia, characterized by the passage of bright red blood through the rectum. However, in cases of profuse upper GI bleeding, hematochezia can also occur. Melena, often indicative of an upper GI source, can occasionally arise from hemorrhage in the small bowel or right side of the colon [13]. In cases of bleeding Meckel's diverticulum, pediatric patients usually experience painless hematochezia, while adults more commonly present with melena [14]. Interestingly, our 18-year-old patient presented with hematochezia, complicating the diagnostic process and indicating the severity of the bleeding.

The diagnostic approach to lower GI bleeding is determined by both the clinical presentation and hemodynamic stability. In

hemodynamically stable patients, colonoscopy remains a first-line diagnostic study with a high diagnostic yield, as supported by contemporary consensus and imaging guidance from the American College of Gastroenterology and Society of Abdominal Radiology [15]. For hemodynamically unstable patients, CT angiography is recommended as the preferred initial modality in current practice [16]. Importantly, since hematochezia can result from either lower or upper GI bleeding, upper GI endoscopy is warranted when colonoscopy is inconclusive [17]. If initial diagnostic tests do not identify the bleeding source, other modalities, including radionuclide imaging, CT enterography, catheter angiography, and capsule endoscopy, are used to aid diagnosis, with choice guided by clinical presentation, stability, and local expertise [18,19].

Our patient underwent an extensive diagnostic workup, including a contrast-enhanced CT scan, sigmoidoscopy, colonoscopy, EGD, and capsule endoscopy. However, none of these investigations identified the source of bleeding. CT angiography was not deemed appropriate, as it requires active arterial bleeding at a minimum rate of 0.5 mL per minute to detect contrast leakage [20]. Since the bleeding had stopped and the patient was hemodynamically stable, this method was not suitable. In contrast, radionuclide imaging is more sensitive, capable of detecting bleeding at rates as low as 0.1 mL per minute [21].

A large review of 1559 patients identified diverticulosis as the leading cause of lower GI bleeding in the adult population, accounting for 5% to 42% of cases. Other causes included ischemia, anorectal abnormalities, polyps and malignancies,

Table 1. Summary of reported cases of bleeding Meckel's diverticulum among adult patients, reported over the period between 2006 and 2023.

Case	Author	Year	Age	Sex	Nature of Bleeding	Diagnostic Tools	Operation
1	Our case	2024	18	Male	Fresh rectal bleeding	CT scan Sigmoidoscopy Colonoscopy EGD Capsule endoscopy Meckel's scan	Laparoscopic segmental resection
2	Dumper et al [14]	2006	31	Male	Bright per rectal bleeding	Colonoscopy Endoscopy Mesenteric angiogram Meckel's scan	Segmental resection
3	Saad Eddin et al [29]	2023	44	Male	Fresh rectal bleeding	CT scan Colonoscopy Meckel's scan	Open segmental resection
4	Krstevski et al [30]	2021	33	Female	Maroon-colored loose stools	Abdominal ultrasound Colonoscopy Endoscopy Video capsule endoscopy Meckel's scan	Laparoscopic diverticulectomy
5	Fernandes et al [31]	2015	64	Male	Hematochezia	Colonoscopy Endoscopy Capsule enteroscopy	Laparoscopic diverticulectomy

Abbreviations: CT, computed tomography; EGD, esophagogastrroduodenoscopy.

angiodysplasia, polypectomy, inflammatory bowel disease, and radiation colitis [22]. Notably, Meckel's diverticulum is not typically listed among these causes in adults, but it warrants a high level of suspicion, especially in younger adults, necessitating a Meckel's scan [23]. In our case, despite being classified as an adult, the patient's young age justified suspicion of Meckel's diverticulum after initial investigations were negative, leading to a Meckel's scan that ultimately confirmed the diagnosis.

Meckel's diverticulum is an uncommon cause of GI bleeding in adults, accounting for a small proportion of cases compared with the pediatric population, in whom diagnostic and management strategies are better established [3]. In adults, no dedicated, evidence-based guidelines exist for the diagnosis or management of Meckel's diverticulum, largely due to its rarity and the predominance of retrospective studies and case series [3,24,25]. Consequently, clinical decision-making is guided by extrapolation from pediatric data, general principles of gastrointestinal bleeding evaluation, and expert consensus [3,26].

The management of symptomatic Meckel's diverticulum typically involves surgical intervention, which can be performed

laparoscopically or via an open technique. The procedure is either simple diverticulectomy or Segmental resection [10]. Segmental resection, involving resection of the small bowel containing the diverticulum, is indicated when simple diverticulectomy may cause narrowing of the small bowel, or in cases of a diverticulum with a wide neck (>2 cm), palpable pathology at the diverticulum base, or a diverticulum with a height-to-diameter ratio less than 2 cm. Following excision, anastomosis is performed using either hand-sewn or stapled techniques [27,28]. In our case, segmental resection was performed to ensure a clear margin, utilizing a linear stapler.

A case report by Dumper et al [14] reported a 31-year-old male patient with a bleeding Meckel's diverticulum, presenting similarly to our patient with bright per rectal bleeding, shortness of breath, light-headedness, fatigue, and headache. Initially, the patient was hemodynamically unstable and required volume resuscitation, mirroring the management approach in our case. Despite undergoing colonoscopy, endoscopy, and mesenteric angiogram, the source of bleeding remained unknown, paralleling our patient's diagnostic journey. Ultimately, the diagnosis was confirmed by a Meckel's scan, and the patient underwent segmental resection.

Saad Eddin et al [29] published a case of a 44-year-old male patient who presented with per rectal bleeding and pre-syncope symptoms. Despite being vitally stable except for tachycardia, he experienced a significant decrease in hemoglobin level from 12.1 g/dL to 9.4 g/dL. Following volume resuscitation, an abdominal and pelvic CT scan was performed, which, unlike our patient's CT scan, demonstrated arterial extravasation from the ileum, indicating active arterial bleeding. Subsequent colonoscopy did not identify the cause of bleeding. Ultimately, a Meckel's scan revealed the presence of Meckel's diverticulum, which was successfully resected via open segmental small bowel resection.

In contrast to our patient, who presented with painless hematochezia and hypovolemia symptoms, Krstevski et al [30] described a 33-year-old female patient who had maroon-colored loose stools, abdominal pain and tenderness, bloating, and leukocytosis (leukocytes $20.1 \times 10^9/L$). The patient also experienced a syncopal episode and a remarkable drop in hemoglobin to 82 g/L. Similar to our case, initial diagnostic modalities, including abdominal ultrasound and upper and lower endoscopies, were unremarkable. In contrast to our case, video capsule endoscopy identified a single diverticulum in the terminal ileum. A Meckel's scan was ultimately necessary for establishing the diagnosis of Meckel's diverticulum. Notably, the patient underwent a non-emergent laparoscopic diverticulectomy after a 4-month course of proton pump inhibitors.

Fernandes et al [31] reported a case of an elderly patient with a bleeding Meckel's diverticulum. The patient was a 64-year-old man who presented to the emergency department with recurrent hematochezia, but whose condition was otherwise vitally, clinically, and laboratory stable. Similar to our case, upper and lower endoscopies were inconclusive. However, capsule enteroscopy revealed a large solitary diverticulum in the middle ileum. Unlike our case, the multidisciplinary team opted for laparoscopic diverticulectomy without a confirmatory Meckel's scan.

Notably, most of the discussed cases in **Table 1** presented with hematochezia, rather than melena, which is typically considered

a more common presentation in adult patients with bleeding Meckel's diverticulum. In addition, colonoscopy and EGD were inconclusive in all cases, whereas CT scans and video endoscopy provided clues about the source of bleeding. However, a Meckel's scan was necessary to confirm the diagnosis in most cases, except that by Fernandes et al. Lastly, both surgical interventions, diverticulectomy and segmental resection, were effective when indicated.

Conclusions

Acute lower GI bleeding is a life-threatening condition requiring prompt resuscitation before diagnostic procedures. While Meckel's diverticulum is a common cause of lower GI bleeding in children, it poses a diagnostic challenge in adults, necessitating a higher index of suspicion. Although Meckel's diverticulum is not typically listed among the causes of lower GI bleeding in adults, it should be suspected in cases with inconclusive initial investigations, particularly in younger adults. In such diagnostically challenging cases, a Meckel's scan can resolve the diagnostic dilemma, and surgical management with diverticulectomy or segmental resection can provide definitive treatment.

Department and Institution Where Work Was Done

Department of Surgery, King Fahad University Hospital, Al-Khobar, Saudi Arabia.

Declaration About Informed Consent

Informed consent was obtained from the patient.

Declaration of Figures' Authenticity

All figures submitted have been created by the authors who confirm that the images are original with no duplication and have not been previously published in whole or in part.

References:

1. Lequet J, Menahem B, Alves A, Fohlen A, Mulliri A. Meckel's diverticulum in the adult. *J Visc Surg.* 2017;154:253-59
2. Sagar J, Kumar V, Shah DK. Meckel's diverticulum: A systematic review. *J R Soc Med.* 2006;99(10):501-5
3. Hansen CC, Søreide K. Systematic review of epidemiology, presentation, and management of Meckel's diverticulum in the 21st century. *Medicine (Baltimore).* 2018;97(35):e12154
4. Uppal K, Tubbs RS, Matusz P, et al. Meckel's diverticulum: A review. *Clin Anat.* 2011;24(4):416-22
5. Rattan KN, Singh J, Dalal P, Rattan A. Meckel's diverticulum in children: Our 12-year experience. *Afr J Paediatr Surg.* 2016;13(4):170-74
6. St-Vil D, Brandt ML, Panic S, et al. Meckel's diverticulum in children: A 20-year review. *J Pediatr Surg.* 1991;26(11):1289-92
7. Kuru S, Kismet K. Meckel's diverticulum: Clinical features, diagnosis and management. *Rev Esp Enferm Dig.* 2018;110(11):726-32
8. Titley-Diaz WH, Aziz M. Meckel scan. Treasure Island (FL): StatPearls Publishing. 2023 Jul 25
9. Kovacs M, Botstein J, Braverman S. Angiographic diagnosis of Meckel's diverticulum in an adult patient with negative scintigraphy. *J Radiol Case Rep.* 2017;11(3):22-29
10. Ruscher KA, Fisher JN, Hughes CD, et al. National trends in the surgical management of Meckel's diverticulum. *J Pediatr Surg.* 2011;46(5):893-96
11. Hussain H, Lapin S, Cappell MS. Clinical scoring systems for determining the prognosis of gastrointestinal bleeding. *Gastroenterol Clin North Am.* 2000;29:445-64

12. Barkun AN, Bardou M, Kuipers EJ, et al. International consensus recommendations on the management of patients with nonvariceal upper gastrointestinal bleeding. *Ann Intern Med.* 2010;152:101-13
13. Zuckerman GR, Trellis DR, Sherman TM, Clouse RE. An objective measure of stool color for differentiating upper from lower gastrointestinal bleeding. *Dig Dis Sci.* 1995;40:1614-21
14. Dumper J, Mackenzie S, Mitchell P, et al. Complications of Meckel's diverticula in adults. *Can J Surg.* 2006;49(5):353-57
15. Strate LL, Gralnek IM. ACG Clinical Guideline: Management of patients with acute lower gastrointestinal bleeding. *Am J Gastroenterol.* 2016;111(4):459-74
16. Loffroy R, Guiu B, Cercueil JP, et al. Multidetector CT angiography in acute gastrointestinal bleeding: Why, when, and how. *Radiographics.* 2021;41(1):E35-E54
17. Laing CJ, Tobias T, Rosenblum DI, et al. Acute gastrointestinal bleeding: Emerging role of multidetector CT angiography and review of current imaging techniques. *Radiology.* 2020;294(1):52-64
18. Expert Panel on Gastrointestinal Imaging; American College of Radiology. ACR Appropriateness Criteria® Lower Gastrointestinal Bleeding. *J Am Coll Radiol.* 2022;19(5S):S126-S37
19. Expert Panel on Gastrointestinal Bleeding; Society of Abdominal Radiology, American College of Gastroenterology. The role of imaging in gastrointestinal bleeding: ACG-SAR consensus recommendations. *Am J Gastroenterol.* 2024;119(3):343-62
20. Kuhle WG, Sheiman RG. Detection of active colonic hemorrhage with use of helical CT: Findings in a swine model. *Radiology.* 2003;228:743-52
21. Dusold R, Burke K, Carpentier W, Dyck WP. The accuracy of technetium-99m-labeled red cell scintigraphy in localizing gastrointestinal bleeding. *Am J Gastroenterol.* 1994;89:345-48
22. Strate LL. Lower GI bleeding: Epidemiology and diagnosis. *Gastroenterol Clin North Am.* 2005;34:643-64
23. Zuccaro G. Management of the adult patient with acute lower gastrointestinal bleeding. American College of Gastroenterology. Practice Parameters Committee. *Am J Gastroenterol.* 1998;93:1202-8
24. Yagnik VD, Garg P, Dawka S. Should an incidental Meckel diverticulum be resected? A systematic review. *Clin Exp Gastroenterol.* 2024;17:147-55
25. Parvanescu A, Bruzzi M, Douard R, et al. Complicated Meckel's diverticulum in adults: Presentation and role of exploratory laparoscopy. *Medicine (Baltimore).* 2018;97(42):e12857
26. Park JJ, Wolff BG, Tollefson MK, et al. Meckel diverticulum: The Mayo Clinic experience with 1476 patients (1950-2002). *Ann Surg.* 2005;242(3):529-33
27. Rivas H, Cacchione RN, Allen JW. Laparoscopic management of Meckel's diverticulum in adults. *Surg Endosc.* 2003;17(4):620-22
28. Varcoe RL, Wong SW, Taylor CF, Newstead GL. Diverticulectomy is inadequate treatment for short Meckel's diverticulum with heterotopic mucosa. *ANZ J Surg.* 2004;74(10):869-72
29. Saad Eddin A, Chowdhury AJ, Saad Aldin E. Meckel's diverticulum: Unusual cause of significant bleeding in an adult male. *Radiol Case Rep.* 2023;18(10):3608-11
30. Krstevski G, Isahi U, Andreevski V. Bleeding Meckel's diverticulum in a 33-year-old female diagnosed with video capsule endoscopy and a technetium-99m pertechnetate scan with a favorable response to H2 blocker and PPI. *Case Rep Gastrointest Med.* 2021;2021:1381395
31. Fernandes C, Pinho R, Carvalho J. Meckel's diverticulum: A rare cause of overt obscure gastrointestinal bleeding in an adult male. *GE Port J Gastroenterol.* 2015;22(3):121-22