






Received: 2025.12.11
Accepted: 2026.04.28
Available online: 2026.05.27
Published: 2026.XX.XX

Complex Endovascular Management of a Giant Ruptured Aortic Arch and Descending Aneurysm Following Prior Endovascular Aneurysm Repair: A Case Report

Authors' Contribution:
Study Design A
Data Collection B
Statistical Analysis C
Data Interpretation D
Manuscript Preparation E
Literature Search F
Funds Collection G

ABCDEF G 1 **Weronika Niewiarowska** 
BCDE 2 **Jerzy Leszczyński** 
BD 2 **Tomasz Jakimowicz** 
BD 2 **Katarzyna Jama** 
DEG 2 **Zbigniew Gałązka** 

1 Medical University of Warsaw, Warsaw, Poland
2 Department of General, Vascular, Endocrine and Transplant Surgery,
Medical University of Warsaw, Warsaw, Poland

Corresponding Authors: Weronika Niewiarowska, Phone: +48 668 221 726, e-mail: niewiarowska.w2@gmail.com; Jerzy Leszczyński, Phone: +48 603 606 962, e-mail: jleszcz1@gmail.com
Financial support: None declared
Conflict of interest: None declared





Patient: Male, 66-year-old
Final Diagnosis: Aortic arch aneurysm • giant ruptured aortic arch and descending aneurysm
Symptoms: Abdominal pain • chest pain • hypotension • shock
Clinical Procedure: Endovascular treatment • triple arch branch repair
Specialty: Surgery

Objective: Unusual clinical course
Background: This case report presents a groundbreaking approach to treating a giant ruptured aortic arch aneurysm in a patient who previously underwent endovascular aneurysm repair (EVAR).
Case Report: A 66-year-old man was admitted for surgical intervention due to a ruptured aortic arch aneurysm. He presented with shock, hypotension, hemorrhage into the left pleura, and chest and abdominal pain. He had a history of EVAR 10 years prior. An urgent computed tomography angiography revealed a ruptured aortic arch aneurysm, 12 cm in diameter, with a descending thoracic aorta segment with features of rupture to the pleura, displacing the trachea, and compressing the left main bronchus. The diameter of the ascending aorta was within normal limits and the abdominal aorta was slightly dilated, with the right stent-graft leg ending in a right common iliac artery aneurysm. As a result, the patient was deemed ineligible for cardiac surgery and qualified for an endovascular procedure, which involved a triple-branched total endovascular arch repair, showcasing significant technical innovation. A right-sided iliofemoral graft was performed with a vascular prosthesis. Completion angiography demonstrated patent branches and successful exclusion of the aneurysm. Despite intensive care following the operation, growing multiorgan failure associated with the patient's multiple concomitant diseases contributed to his eventual death.

Conclusions: The case highlights the feasibility and effectiveness of this advanced technique in managing complex aortic pathologies, even in patients with prior interventions. The importance of this method as a viable option for complicated cases is emphasized, offering insights into potential improvements in patient outcomes.

Keywords: Aneurysm, Aortic Arch • Aneurysm, Ruptured • Aortic Aneurysm, Abdominal • Aortic Aneurysm, Thoracic • Aortic Rupture • Dissection, Thoracic Aorta • Endovascular Aneurysm Repair • Endovascular Procedures • Vascular Surgery

Full-text PDF: <https://www.amjcaserep.com/abstract/index/idArt/952409>

 2594  —  5  31

Publisher's note: All claims expressed in this article are solely those of the authors and do not necessarily represent those of their affiliated organizations, or those of the publisher, the editors and the reviewers. Any product that may be evaluated in this article, or claim that may be made by its manufacturer, is not guaranteed or endorsed by the publisher



Introduction

Open surgical repair serves as the established standard of care for managing aortic arch aneurysms. Nevertheless, patients presenting with significant comorbidities could derive advantages from a minimally invasive strategy. A total arch replacement, which requires sternotomy, cardiopulmonary bypass (extracorporeal circulation), and deep hypothermic circulatory arrest remains the established standard of care for managing aortic arch aneurysms [1,2]. However, according to studies, the 1-year mortality rate following total arch replacement for aortic aneurysm is roughly 81%, compared with the almost 92% 30-day mortality rate associated with such risk factors as stroke, respiratory failure, renal failure, and bleeding reoperation [3,4]. These elements emphasize how crucial it is to thoroughly evaluate risks and take the patient's general health into account before performing surgery. Elderly patients presenting with several significant comorbidities, who are not candidates for open surgery, could potentially benefit from a minimally invasive endovascular strategy [5], facilitated by advanced technologies, including the hybrid aortic arch replacement and implementation of branched aortic arch stent grafts [6]. Performing thoracic endovascular aortic repair (TEVAR) in patients who have previously undergone endovascular aortic repair (EVAR) introduces unique technical and clinical challenges, primarily stemming from increased aortic stiffness, reduced vascular access options, and a higher risk of spinal cord ischemia [31]. This instance demonstrates that the final therapy modality is not just a novel approach but may also prove to be the sole viable management alternative in patients with ruptured unrecognized thoracic aortic aneurysms (TAAs), which show a general mortality of over 90% [10].

Case Report

A 66-year-old man was admitted from the emergency department, for surgical intervention, due to a ruptured aortic arch aneurysm, with signs of shock (confusion, hemoglobin level of 5.8 g/dL, oliguria), hypotension (blood pressure of 85/60 mmHg with a pulse of 55 beats per minute), and reported chest and abdominal pain. Admission lactate level was 5.8 mmol/L; reference range: 0.5-1.5 mmol/L, eGFR level was 10 and serum creatinine level was 5.32. On auscultation, there was a muffled murmur over the left lung.

The patient had a history of hypertension, nicotine use, and endovascular treatment of ruptured abdominal aortic aneurysm (EVAR), 10 years prior. After the EVAR, he failed to make an appointment for any medical follow-up visits, although a follow-up was supposed to take place once a year. This follow-up was also supposed to include an assessment of the thoracic

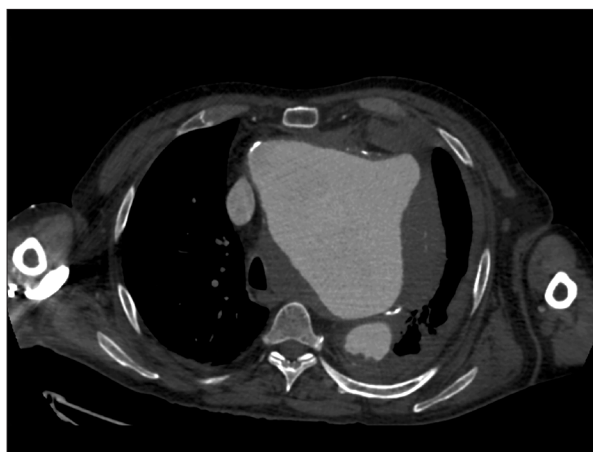


Figure 1. The emergency CT scan, showing visible giant aneurysm with rupture to the pleura. CT, computed tomography.

aorta via computed tomography (CT) scan. He had not been diagnosed with Marfan syndrome, Ehlers-Danlos syndrome, or any other genetic connective tissue disorders.

Morphine (5 mg) was administered twice, subcutaneously. Intravenous and intra-arterial lines were inserted. Through these, 500 mL of Gelaspan and a continuous infusion of 0.15 µg/kg/min of noradrenaline were administered. In addition, 2 doses of 500 mL of Optylite solution were administered, as well as 3 units of red blood cells (RBCs), after which blood pressure improvement was achieved. Oxygen was continuously supplemented via a simple face mask (flow rate 10 L/min) and limb warming was used to manage hypothermia.

An emergency CT scan (**Figure 1**) and computed tomography angiography (CTA) of the aorta revealed a >12 cm in diameter aortic arch aneurysm including an initial segment of the descending thoracic aorta with a free rupture, hematoma in the left pleura, displacement of the trachea, and compression of the left main bronchus. The 3-dimensional reconstruction (**Figure 2**) showed an abdominal stent graft that had been previously implanted into the ruptured abdominal aortic aneurysm. The abdominal aorta was slightly dilated in the post-EVAR section, with the right stent-graft leg ending in a right common iliac artery aneurysm, with a diameter of 35 mm. Fluid was also visible in the pericardial sac, calcifications in the coronary arteries, and hypodense changes in the kidneys.

The departing brachiocephalic trunk (BCT), left common carotid artery (LCCA), and left subclavian artery (LSA) (compressed in the initial segment) were patent (**Figure 3**). The non-aneurysmal ascending aorta was approximately 26 mm in diameter, ie suitable for endovascular treatment in the form of stent graft implantation – providing an appropriate landing zone.

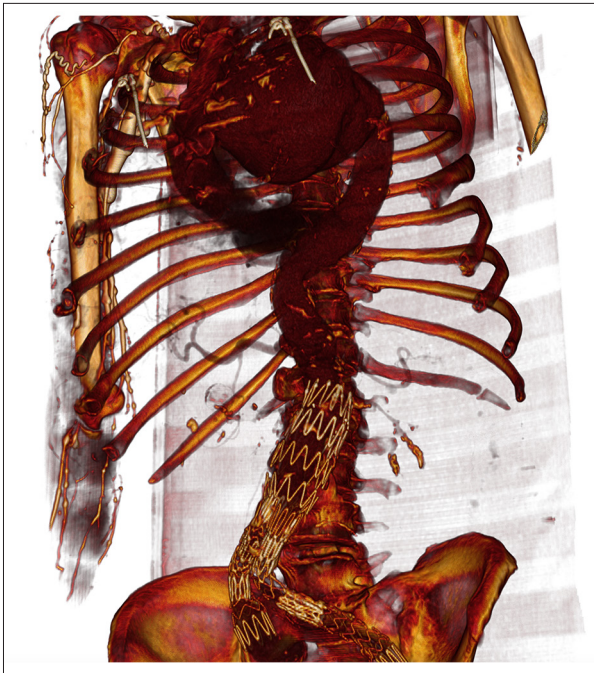


Figure 2. A 3-dimensional reconstruction of a CTA, including a giant arch and descending aneurysm and an abdominal stent graft previously implanted into the ruptured abdominal aortic aneurysm. CTA, computed tomography angiography.

After a cardiac surgery consultation, the patient was deemed ineligible for open surgical repair owing to the elevated procedure risk associated mainly with his unstable general condition (shock) and significant comorbidities. These conditions conferred an excessively high risk of death associated with extracorporeal circulation induction. Due to these issues and his suitable anatomy, he was qualified by vascular surgeons (who had been asked for their advice) for endovascular treatment - implementation of a triple arch branch stent graft. Previous EVAR, as a treatment for rupture of an abdominal aortic aneurysm that was 68 mm in diameter, resulted in the implementation of a bifurcated Zenith Flex AAA Endovascular Graft (Cook Medical, Bloomington, IN, USA). Running the system via its branches was a technical challenge, especially due to atherosclerosis of the iliac arteries and the significant size of the implanted catheter – 24 Fr (8 mm) combined with the dimensions of the stent-graft legs – 11 mm and 12 mm. Initial attempts to introduce the system through the branches were ineffective due to snagging on material in the vessel. However, it was made achievable by the use of dilators and 2 Lunderquist Extra Stiff Wire Guides (Cook Medical, IN, USA); one maintaining the shape of the vessel and the other inserting the arch branch system, in parallel to the rigid one and approaching through the right axillary artery. Intraoperative imaging revealed that the diameter of the aneurysm was even larger than previously indicated by CT and was approximately 14 cm.

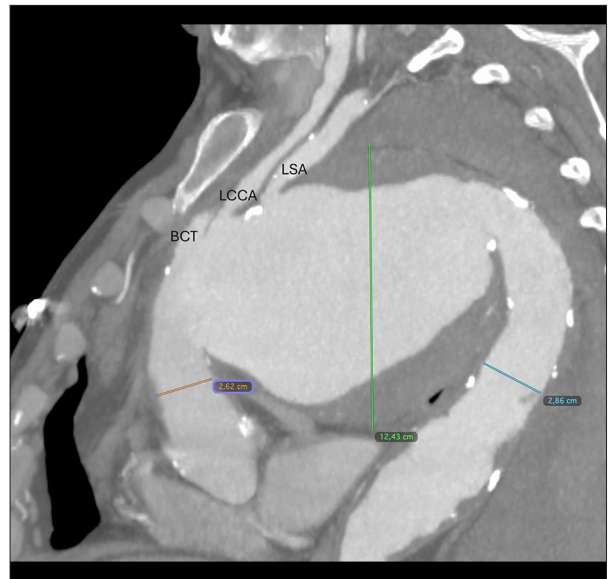


Figure 3. Computed tomography showing 3 vessels departing from the ruptured aneurysm: brachiocephalic trunk (BCT), left common carotid artery (LCCA) and left subclavian artery (LSA). Measured dimensions of the aortic segments: ascending aorta (orange mark), aneurysmal ascending aorta (green mark), and descending aorta below the aneurysm (blue mark).

Finally, after opening the stent graft (a Zenith Arch Branched Graft; Cook Medical, Bloomington, IN, USA), 3 branches were implanted (**Figure 4**): into the BCT (through the right subclavian artery), LCCA, and LSA. The implantations were conducted via a femoral approach, because as they are the inner branches, facing away from the blood flow, they could be introduced and cannulated from below. Then, the system was extended using 2 thoracic stents – a 40 mm in diameter and 21.6 cm in length Zenith TX2 TAA Endovascular Graft and a 40 mm in diameter and 21.7 cm in length Zenith Alpha Thoracic Endovascular Graft Proximal Component (Cook Medical, Bloomington, IN, USA), the distal one ending above the coeliac trunk. The stent graft branches were extended as well, as follows: a Zenith custom-made steel branch (Cook Medical, Bloomington, IN, USA) was used for extension to the BCT, and 2 GORE VIABAHN Endoprostheses (W.L. Gore & Associates, Inc. Flagstaff, AZ, USA) – one 10 mm in diameter and 10 cm in length and the other 13 mm in diameter and 10 cm in length, were used for extension to the LCCA and the LSA, respectively. The final angiography (**Figure 5**) revealed a correctly positioned arch branch and patency of the 3 branches without endoleaks. Completion angiography demonstrated patent branches and successful exclusion of the aneurysm.

A right-sided iliofemoral graft was then performed with a 9 mm in diameter vascular Dacron prosthesis sewn into the initial section of the right external iliac artery and 2 GORE VIABAHN

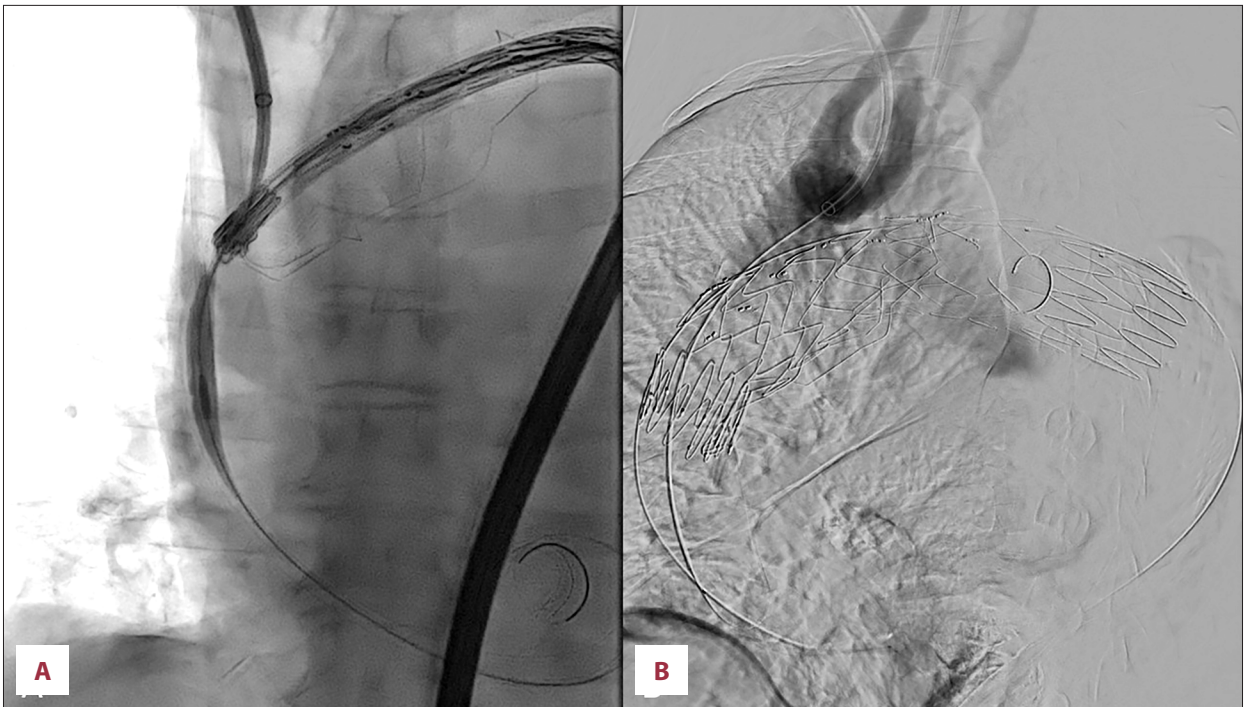


Figure 4. Angiography demonstrating successful implementation. **A** – before opening the stent graft, **B** – after opening.

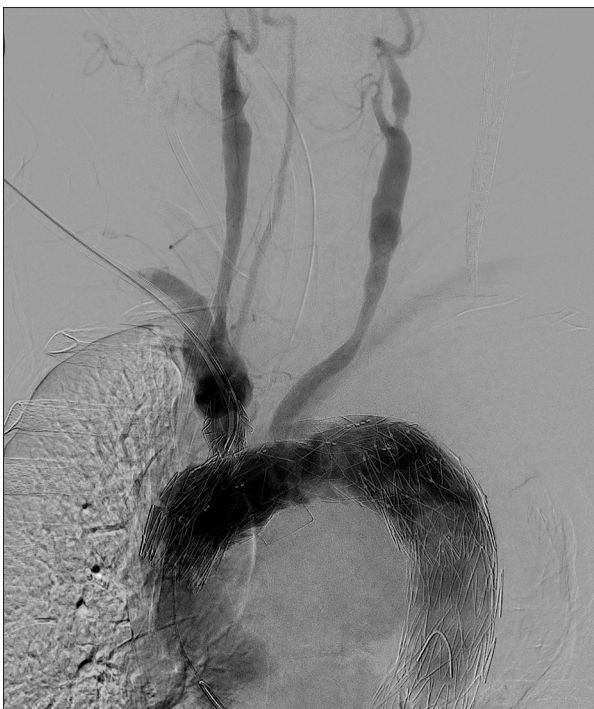

Figure 5. Completion angiography demonstrating patent branches and successful exclusion of the aneurysm.

Endoprostheses were implanted to perform better sealing of the artery (three grafts were finally placed in the right external iliac artery).

The patient's condition deteriorated during the surgery despite the supply of a total of 11 units of RBCs, 6 units of fresh frozen plasma, and 2 units of platelets. Several drops in blood pressure and cerebral oxygen saturation were observed, but with the exception of a marked reduction in cardiac contractility, intraoperative echocardiography revealed no significant abnormalities or indications of tamponade. Total blood loss was 1500 mL. The duration of the operation was 6 hours and the total radiation dose was 1.008 Gy. Neuroprotection strategy included moderate hypothermia, selective antegrade cerebral perfusion, near-infrared spectroscopy, flushing of the device with carbon dioxide, followed by flushing of the carbon dioxide with heparinized saline, a “branch-first” approach, heparin administration, and pharmacotherapy.

Following the procedure, the patient remained in the intensive care unit (ICU), intubated, mechanically ventilated, and under anesthesia. He was hemodynamically unstable, requiring vasopressor support with adrenaline and noradrenaline in increasing doses, exhibiting anemia (hemoglobin level of 10.1 g/dL), increasing lactic acidosis (pH level of 7.1, lactate level of 17 mmol/L; reference range: 0.5-1.5 mmol/L) and anuria (he underwent slow continuous extended dialysis after surgery). His pulse was within the limits of 80-100 beats per minute, he had regular sinus rhythm with periodic tachycardia

and showed no clinical signs of bleeding. Continuous temperature monitoring was implemented. Coagulation and hematologic parameters were regularly assessed. Heparin was given in accordance with activated partial thromboplastin time measured every 6 hours (infusion 50 000 units per 50 mL), electrolyte imbalances were corrected, perioperative antibiotic treatment was continued, and anti-ulcer prophylaxis was implemented. Despite comprehensive intensive care, there were indications of growing multiorgan failure associated with the patient's multiple concomitant diseases and serious condition at the time of admission. Increasing hypotension despite the use of resuscitation doses of catecholamines contributed to cardiac arrest the day after surgery.

Discussion

Aortic arch aneurysms usually indicate the proximal extension of thoracic and thoraco-abdominal aortic aneurysms or the distal extension of ascending aortic disease [7]. The aortic arch accounts for 21.3% and the descending thoracic aorta for 34.6% of the population's total estimated incidence of TAAs, which is 5.3 per 100 000 people annually. Ruptures of TAAs were estimated to occur at a rate of 1.6 per 100 000 annually. It has been demonstrated that a dilated segment of the aorta is a predictor of having a dilation in another segment. Abdominal aortic aneurysm surgery has been performed on 12.4% of patients with TAAs. Patients with abdominal aortic aneurysm have a 2.2% probability of developing a TAA [8].

Common risk factors, like genetic susceptibility to multiple thoracic and abdominal aortic aneurysms, such as Marfan, Ehlers-Danlos, or Loews-Dietz syndromes, may increase the likelihood of having 2 aneurysms in different parts of the aorta [9-11]. The fact that no nongenetic cardiovascular risk factor, such as nicotine, high blood pressure, or male sex, is sufficient to develop aortic aneurysms at 1 or more sites further suggests that patients with numerous aneurysms should be expected to have genetic susceptibilities [8].

Although our patient did not have any of the genetic conditions mentioned above, due to ruptured aneurysms, he had been admitted on an emergency basis for intervention. Therefore, he had not been tested for the presence of mutations in genes determining other connective tissue defects. His family history is also unknown, hence familial thoracic aneurysm and/or dissection (FTAAD) cannot be ruled out.

This case highlights the importance of lifelong surveillance after EVAR. In accordance with the guidelines, which include the most recent ones at the time of his initial intervention [12], as well as those that were in effect after his initial intervention [13], the patient should have been undergoing a follow-up

annually, including a CT scan of the thoracic aorta. His failure to attend follow-up exams resulted in an extremely uncommon circumstance: occurrence of an aortic aneurysm of this magnitude after prior treatment for a ruptured aneurysm. Such an occurrence is essentially not described in contemporary sources. This is particularly relevant given research demonstrating the value of this follow-up in identifying aneurysms of the thoracic aorta: the incidence of TAA over time ranges from 2.2% at the mean treatment follow-up of 5 years to as high as 12.6% after the diagnosis of abdominal aortic aneurysm, so it is not unusual [14,15].

The treatment of diseases of the aortic arch is becoming increasingly complex and multidisciplinary [16]. There are several methods for performing total endovascular aortic arch stent grafting, including branched devices, fenestrated grafts, and the chimney technique [1,17,18]. According to European Association for Cardio-Thoracic Surgery/Society of Thoracic Surgeons (EACTS/STS) and American College of Cardiology/American Heart Association (ACC/AHA) guidelines, to qualify for arch replacement, patients should be low to moderate in surgical risk. For symptomatic high-risk patients, endovascular treatment should be considered [19,20]. Endovascular aortic arch repair, including zone 0, should be considered in patients unfit for open surgery and with a suitable anatomy [21,22]. This approach entails, but is not limited to, the following: appropriate landing zone diameter and length; appropriate supra-aortic target vessels in terms of size, tortuosity, presence of dissection, and take-off angle; appropriate access site (carotid, axillary, femoral, or similar); absence of an excessive inner arch curvature; and appropriate coronary ostia height [1]. In our patient, these criteria were met, and despite the difficulties with the femoral approach, successful reconstruction was nevertheless achieved.

Taking into consideration that secondary interventions are needed in 31% of patients [23], the chosen course of the procedure should also cover possible future treatment options, particularly for individuals who are at risk of developing aneurysms in this location. The extension of the branched stent graft was intended to facilitate potential T-branch [24] or unibody endograft [25] insertion, providing a more tailored diameter of the descending aorta.

The results of a study aiming to assess the appropriateness of zone 0 TEVAR as the first-line therapy for aortic arch aneurysms in emergency settings refer to TEVAR as an alternative suitable for high-risk patients with arch aneurysms who need zone 0 landing, but it is nevertheless not a reliable method [28]. However, in comparison with hybrid TEVAR, zone 0 branched TEVAR may be considered an effective and more minimally invasive treatment for high-risk patients and thus might be superior to a hybrid approach [29].

According to the literature, in addition to having greater incidence of stroke, pneumonia, and the need for extended breathing support (all $P \leq 0.01$), ruptured TAA patients treated endovascularly have significantly worse 30-day survival than patients with incorporated TAAs (69.2% vs 96.9%; $P < 0.001$). Ruptured TAA patients as a whole have lower long-term survival than incorporated TAA patients at 1 year (46% vs 86%), 5 years (27% vs 48%), and 8 years (20% vs 32%; all $P < 0.001$), primarily due to early mortality [30].

Taking into account the condition of the patient at the time of admission, along with the general mortality in cases of ruptured unrecognized TAAs [10], our patient's death was attributable to the described clinical scenario. Rupture of the giant aortic arch aneurysm precipitated profound hypovolemic shock, leading to subsequent multi-organ failure. Despite maximal therapeutic efforts and advanced intensive care support, the outcome was ultimately fatal. However, it is important to emphasize the technical success of the complex procedure, which was the proper intervention in such severe circumstances.

Conclusions

With the progressing development of endovascular technology, the possibilities of methods will become more sophisticated

References:

1. D'Onofrio A, Caraffa R, Cibin G, et al. Total endovascular aortic arch repair: From dream to reality. *Medicina (Kaunas)*. 2022;58(3):372
2. Sethi S, Parekh U. Aortic arch aneurysm. [Updated 2023 Jul 24]. In: StatPearls [Internet]. Treasure Island (FL): StatPearls Publishing; 2025. Available from: <https://www.ncbi.nlm.nih.gov/books/NBK563170/>
3. Rajesh K, Levine D, Murana G, et al. Is surgical risk of aortic arch aneurysm repair underestimated? A novel perspective based on 30-day versus 1-year mortality. *Eur J Cardiothorac Surg*. 2024;65:ezae041
4. Tanaka Y, Mikamo A, Suzuki R, et al. Mortality and morbidity after total aortic arch replacement. *Ann Thorac Surg*. 2014;98(3):1048-53
5. Brown JA, Arnaoutakis GJ, Szeto WY, et al. Endovascular repair of the aortic arch: State of the art. *J Card Surg*. 2021;36(11):4292-300
6. Rudarakanchana N, Jenkins MP. Hybrid and total endovascular repair of the aortic arch. *Br J Surg*. 2018;105:315-27
7. Mirza AK, Oderich GS. Endovascular total arch repair: An overview of the most common indications for reintervention after endovascular arch repair with branched endografts and a discussion of strategies to minimize complications. *Endovascular Today [Internet]* 2022 Mar [cited 2025 Oct 23]. Available from: <https://evtoday.com/articles/2022-mar/endovascular-total-arch-repair>
8. Gouveia E, Melo R, Silva Duarte G, Lopes A, et al. Incidence and prevalence of thoracic aortic aneurysms: A systematic review and meta-analysis of population-based studies. *Semin Thorac Cardiovasc Surg*. 2022;34(1):1-16
9. Liu H, de Bruin JL, Ijpm AS, et al. Increased risk for thoracic aneurysms in female and familial abdominal aortic aneurysm patients. *J Vasc Surg*. 2025;82(2):431-38.e2
10. Mühlstädt K, De Backer J, von Kodolitsch Y, et al. Case-matched comparison of cardiovascular outcome in Loeys-Dietz syndrome versus Marfan syndrome. *J Clin Med*. 2019;8(12):2079
11. Pinard A, Jones GT, Milewicz DM. Genetics of thoracic and abdominal aortic diseases. *Circ Res*. 2019;124(4):588-606
12. Wanhainen A, Gombert A, Antoniou GA, et al. European Society for Vascular Surgery (ESVS) 2026 Clinical Practice Guidelines on the management of descending thoracic and thoraco-abdominal aortic diseases – Editor's choice. *Eur J Vasc Endovasc Surg*. 2026;71(2):172-270
13. Wanhainen A, Verzini F, Van Herzele I, et al. Editor's choice – European Society for Vascular Surgery (ESVS) 2019 Clinical Practice Guidelines on the management of abdominal aorto-iliac artery aneurysms. *Eur J Vasc Endovasc Surg*. 2019;57(1):8-93
14. Iglesias CI, Arenas Azofra E, Busto Suárez S, et al. Incidence of thoracic aortic aneurysms in patients with a previous abdominal aortic aneurysm repair. *Vasc Med*. 2020;25:314-16
15. Chaer RA, Vasoncelos R, Marone LK, et al. Synchronous and metachronous thoracic aneurysms in patients with abdominal aortic aneurysms. *J Vasc Surg*. 2012;56(5):1261-65
16. Lodo V, Centofanti P. Current techniques of repair of aortic arch pathologies and the role of the aortic team. *Indian J Thorac Cardiovasc Surg*. 2024;40(4):451-60
17. Makalosi V, Tsilimparis N, Rohlfes F, et al. Endovascular total arch replacement techniques and early results. *Ann Cardiothorac Surg*. 2018;7(3):380-88
18. Huang W, Ding H, Jiang M, et al. Outcomes of Chimney technique for aortic arch diseases: A single-center experience with 226 cases. *Clin Interv Aging*. 2019;14:1829-40
19. Czerny M, Grabenwöger M, Berger T, et al. EACTS/STS guidelines for diagnosing and treating acute and chronic syndromes of the aortic organ. *Ann Thorac Surg*. 2024;118(1):5-115
20. Isselbacher EM, Preventza O, Black JH 3rd, et al. 2022 ACC/AHA guideline for the diagnosis and management of aortic disease: A report of the American Heart Association/American College of Cardiology Joint Committee on Clinical Practice Guidelines. *Circulation*. 2022;146(24):e334-e482

21. Czerny M, Schmidli J, Adler S, et al. Current options and recommendations for the treatment of thoracic aortic pathologies involving the aortic arch: An expert consensus document of the European Association for Cardio-Thoracic surgery (EACTS) and the European Society for Vascular Surgery (ESVS). *Eur J Cardiothorac Surg.* 2019;55(1):133-62
22. Spath P, Campana F, Tsilimparis N, et al. Outcomes of fenestrated and branched endografts for partial and total endovascular repair of the aortic arch – A systematic review and meta-analysis. *Eur J Vasc Endovasc Surg.* 2024;67(1):106-16
23. Tenorio ER, Oderich GS, Kölbel T, et al. Multicenter global early feasibility study to evaluate total endovascular arch repair using three-vessel inner branch stent-grafts for aneurysms and dissections. *J Vasc Surg.* 2021;74(4):1055-65
24. Tsilimparis N, Fiorucci B, Debus ES, et al. Technical aspects of implanting the t-Branch off-the-shelf multibranched stent-graft for thoracoabdominal aneurysms. *J Endovasc Ther.* 2017;24(3):397-404
25. Essam S, Hussein M, Ahmed AM, et al. Safety evaluation of unibody endografts for abdominal aortic aneurysm repair: A systematic review and meta-analysis. *Ann Vasc Surg.* 2024;108:437-51
26. Rommens KL, Estrera AL. Contemporary management of aortic arch aneurysm. *J Vasc Surg.* 2019;69(6):e175-83
27. Spanos K, Haulon S, Eleshra A, et al. Anatomical suitability of the aortic arch arteries for a 3-inner-branch arch endograft. *J Endovasc Ther.* 2021;28(1):14-19
28. Seike Y, Fukuda T, Yokawa K, et al. Differences of mid term outcomes in debranching thoracic endovascular aortic repair between zone 0 and zone 1-2 landing. *Gen Thorac Cardiovasc Surg.* 2023;71:59-66
29. Kudo T, Kuratani T, Sawa Y, Miyagawa S. Effectiveness and minimal-invasiveness of zone 0 landing thoracic endovascular aortic repair using branched endograft. *J Thorac Cardiovasc Surg.* 2024;167(5):1619-27
30. Fiandero M, Goel NJ, Mosbahi S, et al. Longitudinal outcomes of thoracic endovascular aortic repair for ruptured thoracic aortic aneurysms. *J Thorac Cardiovasc Surg.* 2025;169(6):1645-52.e3
31. Moulakakis KG, Mylonas SN, Kakisis J, et al. Arterial stiffness alterations and inflammatory response following endovascular aortic repair: Based on a presentation at the 2013 VEITH Symposium, November 19-23, 2013 (New York, NY, USA). *Aorta (Stamford).* 2015;3(2):75-80