

Received: 2026.01.17

Accepted: 2026.04.29

Available online: 2026.05.18

Published: 2026.XX.XX

# Vacuum Scaling Drainage in the Treatment of Infected Elbow Charcot Neuroarthropathy: A Case Report and Literature Review

## Authors' Contribution:

Study Design A  
Data Collection B  
Statistical Analysis C  
Data Interpretation D  
Manuscript Preparation E  
Literature Search F  
Funds Collection G

AEF **Hongyuan Yang**

National Research Center for Rehabilitation Technical Aids Affiliated Rehabilitation Hospital, Beijing, PR China


**Corresponding Author:** Hongyuan Yang, e-mail: [y18945219606@163.com](mailto:y18945219606@163.com)**Financial support:** None declared**Conflict of interest:** None declared

**Patient:** Male, 48-year-old  
**Final Diagnosis:** Charcot's arthropathy  
**Symptoms:** Painless joint destruction complicated by infection  
**Clinical Procedure:** —  
**Specialty:** Orthopedics and Traumatology

**Objective:** Rare disease**Background:** Charcot neuroarthropathy (CN) is a rare and easily misdiagnosed neuropathic arthropathy, often secondary to conditions such as syringomyelia and diabetes mellitus. Its clinical course is insidious, making early diagnosis challenging, and the presence of infection further complicates management.**Case Report:** This article reports a case of a 48-year-old male patient with elbow CN and secondary infection due to syringomyelia. The patient presented with swelling, erythema, and elevated skin temperature of the left elbow, but without significant pain. Imaging studies revealed elbow dislocation accompanied by extensive bony destruction. Laboratory test results showed a markedly elevated high-sensitivity C-reactive protein level (62.10 mg/L), and bacterial culture identified *Staphylococcus aureus* infection. After thorough debridement, the patient was treated with vacuum sealing drainage (VSD) combined with intravenous vancomycin for infection control. Following 2 sessions of VSD therapy, the infection was effectively controlled, with good granulation tissue formation, significant reduction in joint swelling, and negative bacterial culture results. At the 6-month follow-up, the elbow remained stable without signs of recurrent infection; the patient reported mild pain and limited range of motion, and definitive reconstructive surgery was deferred due to ongoing risk of infection and patient preference.**Conclusions:** This case suggests that early and thorough debridement combined with VSD is an effective local treatment strategy for CN patients with infection. This approach aids in infection control and promotes wound healing, thereby creating favorable conditions for subsequent functional recovery. VSD, through continuous negative pressure drainage and irrigation, effectively removes necrotic tissue and exudate, improves local microcirculation, and demonstrates good application value in managing CN-related infections.**Keywords:** Case Reports • Orthopedics • Staphylococcal Infections • Syringomyelia • Vacuum • Charcot Joint**Full-text PDF:** <https://www.amjcaserep.com/abstract/index/idArt/952838>
 1758

 —

 1

 10


Publisher's note: All claims expressed in this article are solely those of the authors and do not necessarily represent those of their affiliated organizations, or those of the publisher, the editors and the reviewers. Any product that may be evaluated in this article, or claim that may be made by its manufacturer, is not guaranteed or endorsed by the publisher

## Introduction

Charcot neuroarthropathy (CN) is a rare and easily misdiagnosed clinical condition. It manifests with diverse clinical presentations, commonly including redness, swelling, and elevated skin temperature of the soft tissues around the affected joint, often without significant pain. The disease is named after the French neurologist Jean Martin Charcot, who first described progressive joint destruction in patients with tabes dorsalis [1]. Further research into the disease has revealed that conditions such as diabetes mellitus, alcoholism, rheumatoid arthritis, syphilis, syringomyelia, tabes dorsalis, and heavy metal poisoning can contribute to the development of CN. Due to the current lack of specific diagnostic markers, the diagnosis of CN primarily relies on patient history, clinical presentation, and imaging studies. Beyond early diagnosis, timely and appropriate treatment is crucial for managing the onset and progression of CN, preventing complications such as severe joint deformity and soft tissue ulcers, and averting major adverse outcomes like amputation. Despite advances in understanding, CN complicated by infection remains a particularly challenging clinical scenario, especially when involving the upper extremity, where functional demands are high and surgical options are limited. We report the diagnosis and treatment process of a patient with elbow CN following an infection, with an emphasis on the role of vacuum sealing drainage (VSD) in infection management.

## Case Report

A 48-year-old Chinese man presented with swelling and limited mobility in his left elbow joint for over 10 days. The patient reported that more than 10 days earlier, he had developed redness, swelling, and increased skin temperature in the left elbow joint without an obvious cause and without significant pain. Subsequently, the redness and swelling gradually worsened and was accompanied by restricted joint movement. During this period, he visited a local hospital, where he received a diagnosis of CN and syringomyelia and was treated with debridement and drainage. The patient had a known history of syringomyelia for approximately 5 years, with associated sensory deficits in the bilateral upper extremities, which likely contributed to the delayed recognition of joint pathology.

After admission, magnetic resonance imaging (MRI) and X-ray examinations of the elbow joint were performed. The results indicated alterations in the elbow bone structure and surrounding soft tissues, suggestive of CN complicated by infection, accompanied by elbow dislocation (Figure 1A-1C). MRI revealed extensive bone marrow edema, joint effusion, and periarticular soft tissue swelling, consistent with Eichenholtz stage I to II disease. Concurrently, laboratory test results showed a high-sensitivity C-reactive protein level of 62.10 mg/L (reference

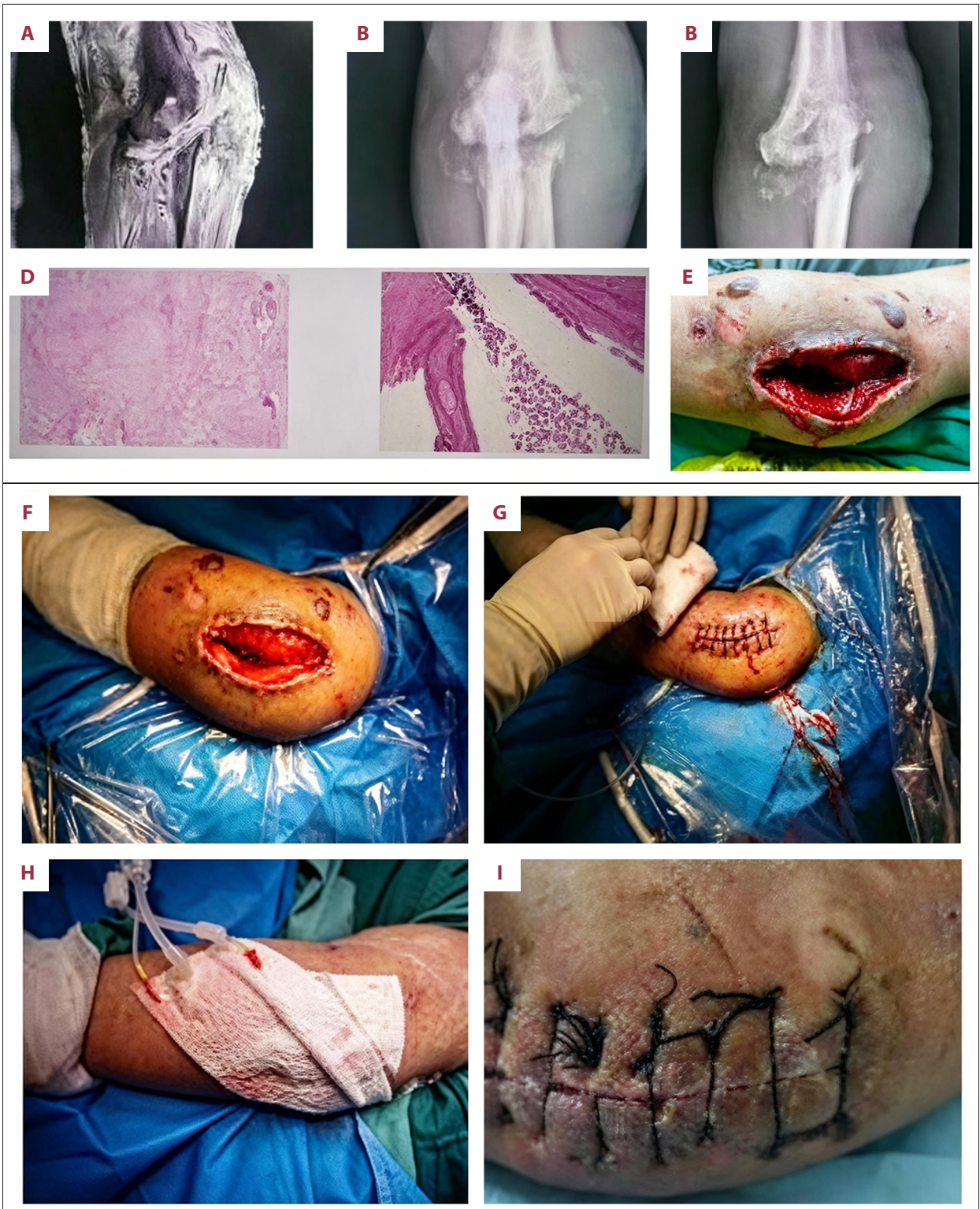
range: 0-3 mg/L), and bacterial culture of the drainage fluid identified *Staphylococcus aureus* infection. Antibiotic susceptibility testing confirmed sensitivity to vancomycin, guiding subsequent antimicrobial therapy.

To control the infection, debridement of the affected limb was performed. Upon removal of the previous drainage device, a significant amount of pus and purulent material was observed in the elbow joint (Figure 1D, 1E). Extensive destruction of the elbow bone was noted, with the elbow joint having lost its original anatomical structure and being dislocated. After thorough debridement, including removal of necrotic tissue and purulent material, the joint was irrigated alternately with povidone-iodine, hydrogen peroxide, and normal saline. No external fixation device was applied during this stage, as the primary goal was infection control; joint reduction was deferred due to the risk of persistent infection and the tenuous condition of the surrounding soft tissues.

A VSD system (Wuhan VSD Medical Science & Technology Co, Ltd, China) was applied for continuous irrigation and drainage. The negative pressure was set at -125 mmHg, with continuous suction. Irrigation was performed using normal saline at a rate of 30 mL/h. The VSD system was selected to provide sustained negative pressure, promote granulation tissue formation, and reduce bacterial load through continuous irrigation. Postoperatively, based on drug sensitivity results, intravenous vancomycin was administered at a dose of 1 g every 12 hours, adjusted for renal function, with therapeutic drug monitoring to ensure adequate trough levels. After 6 days, the patient's symptoms, including limb redness, swelling, and elevated skin temperature, showed improvement.

The VSD device was then removed to assess wound healing. The wound exhibited good blood supply with formation of bright red granulation tissue. Fluid from the joint cavity was collected for bacterial culture, and the wound was again irrigated with povidone-iodine, hydrogen peroxide, and normal saline (Figure 1F). After satisfactory cleaning, the wound was appropriately sutured (Figure 1G), and a new VSD device was applied for continued irrigation and drainage (Figure 1H). The second VSD session lasted 7 days, during which the negative pressure was maintained at -125 mmHg, and irrigation continued at 30 mL/h. Seven days later, significant improvement in elbow swelling was observed, and bacterial culture showed no significant bacterial growth. The VSD device was removed. The surgical incision was healing well, with no redness, swelling, or abnormal discharge. The wound was disinfected and dressed with sterile gauze (Figure 1I).

At the 6-month follow-up, the patient had no recurrent signs of infection. The elbow remained stable, although range of motion was limited to approximately 30° of flexion-extension arc (from



**Figure 1.** (A-C) Magnetic resonance imaging and digital radiography examination of the elbow joint before surgery, showing elbow Charcot neuroarthropathy with infection and elbow dislocation. (D, E) Preoperative wound condition of elbow joint and soft tissue pathological results sent for examination. (F-I) Two vacuum sealing drainage treatment processes and prognosis.

20° to 50° of flexion). The patient reported mild pain (visual analog scale score 2/10) and was able to perform activities of daily living with the contralateral upper extremity compensating for the limited elbow motion. No definitive reconstructive surgery had been performed, as the patient preferred to delay intervention due to the risk of recurrent infection and functional trade-offs. Shared decision-making included discussions comparing elbow arthrodesis and resection arthroplasty, with the patient opting for conservative management with continued follow-up.

## Discussion

This case presented a challenging scenario: a patient with CN of the elbow complicated by secondary infection, extensive bone destruction, and joint dislocation. The primary clinical challenge was to achieve infection control while preserving the potential for future functional reconstruction. The decision to use VSD following debridement was based on its ability to provide continuous negative pressure, remove exudate, and promote granulation tissue formation, which is particularly beneficial in infected joint cavities with compromised soft tissue.

VSD offers several advantages over traditional open drainage or antibiotic-impregnated beads. It maintains a closed, moist environment, reduces the risk of secondary contamination, and improves local microcirculation by reducing edema [4,5]. In the present case, the negative pressure was set at -125 mmHg, which is commonly used for deep joint infections to ensure adequate drainage and tissue adherence. Continuous irrigation with normal saline helped dilute bacterial load and maintain patency of the drainage system. However, VSD also has limitations, including high cost, the need for specialized equipment, and reduced patient mobility during treatment. These factors should be considered when selecting this modality, particularly in upper extremity cases in which patient mobility may be less restricted than in lower extremity applications.

After infection control, the question of definitive management remained. As found in our review of the literature, joint arthroplasty in patients with CN is associated with high complication rates, including periprosthetic joint infection, dislocation, and aseptic loosening [9]. For the elbow, arthrodesis may represent a more reliable option in the setting of neuropathic arthropathy, as it provides stability at the expense of motion. Resection arthroplasty is an alternative but can result in significant instability in a neuropathic joint. In this case, VSD served as a bridge therapy to achieve a clean wound, allowing time for shared decision-making regarding definitive reconstruction vs long-term bracing. At 6 months after treatment, the patient remained infection-free and opted for conservative management, highlighting the importance of patient-centered decision-making in CN management.

The pathogenesis of CN is increasingly understood as involving an imbalance between osteoclast and osteoblast activity, driven by pro-inflammatory cytokines such as tumor necrosis factor  $\alpha$  and interleukin  $1\beta$  [4,5]. Imaging remains central to diagnosis, with MRI offering higher sensitivity than X-rays in detecting early bone marrow edema. The Eichenholtz classification continues to guide staging, with stage I characterized by fragmentation and dislocation [6]. In this case, the patient presented with advanced-stage disease, underscoring the importance of early recognition. The presence of infection further complicates staging and treatment, as inflammatory changes can mimic or exacerbate CN-related bone destruction.

Infection management in CN requires a multidisciplinary approach involving orthopedic surgeons, infectious disease specialists, and wound care teams. The use of VSD in this setting is supported by its ability to achieve negative pressure wound therapy in complex anatomical regions such as the elbow, where joint contours can pose challenges for traditional dressings. Compared with open drainage, VSD reduces the frequency of dressing changes, thereby minimizing patient discomfort and the risk of nosocomial infection. However, careful monitoring is required to ensure adequate irrigation flow and to prevent clogging of the drainage system, which can compromise therapeutic efficacy.

While the literature review on CN pathogenesis and diagnosis is extensive, the focus of this discussion is on the management of infection in CN. The present case demonstrates that VSD, when combined with thorough debridement and appropriate antibiotic therapy, can effectively control infection and create favorable conditions for subsequent functional considerations. Future studies should explore the optimal negative pressure settings, irrigation protocols, and duration of VSD therapy specifically in infected neuroarthropathic joints, as current evidence is largely extrapolated from diabetic foot and posttraumatic infections.

The limitations of this case report include the single-patient nature, lack of long-term follow-up beyond 6 months, and the absence of comparative data with alternative drainage techniques. Additionally, functional outcome assessment was limited to range of motion and pain scores, without validated elbow-specific outcome measures. Nonetheless, this case provides valuable insights into the practical application of VSD in a complex infected CN scenario.

## Conclusions

We present a case of elbow CN with secondary infection successfully managed with thorough debridement and VSD therapy. This approach enabled infection control and wound healing,

providing a stable foundation for long-term management. VSD is a valuable tool in managing infected CN lesions, although careful patient selection and consideration of definitive surgical options remain essential. A multidisciplinary approach and shared decision-making are critical in achieving optimal outcomes in this challenging patient population.

### Acknowledgments

We are extremely grateful to the patient and his family.

### Institution Where Work Was Done

National Research Center for Rehabilitation Technical Aids  
Affiliated Rehabilitation Hospital, Beijing, PR China.

### References:

1. Galeazzi Rech AL, Stüve Y, Toepfer A, Schimke KE. Missing the boat: Fatal ending to a missed case of Charcot arthropathy. *Endocrinol Diabetes Metab Case Rep.* 2020;2020:20-0013
2. Munson ME, Wrobel JS, Holmes CM, Hanauer DA. Data mining for identifying novel associations and temporal relationships with Charcot foot. *J Diabetes Res.* 2014;2014:214353
3. Koeck FX, Bobrik V, Fassold A, et al. Marked loss of sympathetic nerve fibers in chronic Charcot foot of diabetic origin compared to ankle joint osteoarthritis. *J Orthop Res.* 2009;27(6):736-41
4. Jeffcoate WJ, Game F, Cavanagh PR. The role of proinflammatory cytokines in the cause of neuropathic osteoarthropathy (acute Charcot foot) in diabetes. *Lancet.* 2005;366(9502):2058-61
5. La Fontaine J, Shibuya N, Sampson HW, Valderrama P. Trabecular quality and cellular characteristics of normal, diabetic, and Charcot bone. *J Foot Ankle Surg.* 2011;50(6):648-53
6. Hastings MK, Johnson JE, Strube MJ, et al. Progression of foot deformity in Charcot neuropathic osteoarthropathy. *J Bone Joint Surg Am.* 2013;95(13):1206-13
7. Inoue D, Kabata T, Kajino Y, et al. Clinical results of total hip arthroplasty in two patients with Charcot hip joints due to congenital insensitivity to pain with anhidrosis. *Case Rep Orthop.* 2018;2018:1743068
8. Mei F, Li JJ, Lin J, et al. Constrained condylar prostheses for the treatment of Charcot arthropathy: A case report and literature review. *Orthop Surg.* 2023;15(5):1423-30
9. Zhang Z, Chi J, Raso J, et al. Outcomes following total hip arthroplasty in patients who have Charcot Neuroarthropathy of the Hip. *J Arthroplasty.* 2023;38(12):2650-54
10. Botek G, Figas S, Narra S. Charcot neuroarthropathy advances: Understanding pathogenesis and medical and surgical management. *Clin Podiatr Med Surg.* 2019;36(4):663-84

### Informed Consent

The patient allowed personal data processing and informed consent was obtained from the patient. Written informed consent was obtained from the patient for publication of this case report and any accompanying images. A copy of the written consent is available for review by the editor-in-chief of this journal.

### Declaration of Figures' Authenticity

All figures submitted have been created by the authors who confirm that the images are original with no duplication and have not been previously published in whole or in part.