American Journal of Case Reports

e-ISSN 1941-5923
© Am J Case Rep, 2026; 27: e953434
DOI: 10.12659/AJCR.953434

Received: 2026.03.15
Accepted: 2026.09.09
Available online: 2026.11.25
Published: 2026.XX.XX

Orthodromic Atrioventricular Reentrant Tachycardia via a Concealed Left-Sided Accessory Pathway and Dysautonomia in a Young Patient: Diagnostic Pitfalls Arising From Overlapping Syncope and Palpitations

Authors' Contribution:
Study Design A
Data Collection B
Statistical Analysis C
Data Interpretation D
Manuscript Preparation E
Literature Search F
Funds Collection G

DEF 1 Elizabeth Bello Rossette
E 1,2 Elena Soto-Vega

1 School of Health Sciences, Universidad Anáhuac Puebla, Puebla, México
2 School of Medicine, Universidad de la Salud del Estado de Puebla, Puebla, México

Corresponding Author: Elena Soto-Vega, Escuela de Medicina, Universidad de la Salud de Estado de Puebla, Av. Reforma 722, Colonia Centro, Puebla, México, CP 72000
Phone: (+52) 222 541 5200, e-mail: elena.soto20@anahuac.mx

Financial support: None declared
Conflict of interest: None declared

APPROVED GALLEY PROOF

Patient: Female, 21-year-old
Final Diagnosis: Orthodromic atrioventricular reentrant tachycardia (AVRT) via a concealed left-sided accessory pathway
Symptoms: Clinically suspected dysautonomia
Clinical Procedure: —
Specialty: Cardiology
Objective: Rare coexistence of disease or pathology

Background: Orthodromic atrioventricular reentrant tachycardia (AVRT) via a concealed accessory pathway is a supraventricular tachycardia in which the pathway conducts exclusively in the retrograde direction, without surface electrocardiographic evidence of pre-excitation. Dysautonomia comprises disorders of autonomic regulation that present with palpitations, syncope, dizziness, and exercise intolerance. This symptom overlap can delay diagnosis, because anchoring on one condition may mask the other.

Case Report: We present a case of a 21-year-old woman with recurrent tachycardia, chest pain, and syncope since early childhood. Over more than a decade, she underwent multiple Holter recordings and electrophysiological studies without a definitive diagnosis. A reportedly positive tilt table test (original hemodynamic data unavailable) led the treating physicians to a clinical diagnosis of dysautonomia. Despite symptomatic management, her limitations persisted. A later Holter recording showed a short PR interval of 95 ms, and a repeat electrophysiological study induced orthodromic AVRT and identified a concealed left-sided accessory pathway, which was eliminated by radiofrequency catheter ablation. At 1-year follow-up, a 12-lead ECG showed sinus rhythm with a normal PR interval and no delta waves. Symptoms attributed to the clinically suspected autonomic disorder persisted and were managed with lifestyle modifications and pharmacological treatment.

Conclusions: This report highlights the diagnostic challenges that arise when conditions with overlapping symptoms coexist. Clinicians should evaluate arrhythmic and autonomic causes in parallel, reconsider rhythm interpretation when clinical suspicion persists, and counsel patients that autonomic symptoms can continue after successful ablation.

Keywords: Catheter Ablation • Syncope • Accessory Atrioventricular Bundle • Tachycardia, Atrioventricular Nodal Reentry • Diagnostic Errors • Autonomic Nervous System Diseases

Full-text PDF: https://www.amjcaserep.com/abstract/index/idArt/953434

2035 1 4 12

Publisher's note: All claims expressed in this article are solely those of the authors and do not necessarily represent those of their affiliated organizations, or those of the publisher, the editors and the reviewers. Any product that may be evaluated in this article, or claim that may be made by its manufacturer, is not guaranteed or endorsed by the publisher

This work is licensed under Creative Commons Attribution-NonCommercial-NoDerivatives 4.0 International (CC BY-NC-ND 4.0)

Indexed in: [PMC] [PubMed] [Emerging Sources Citation Index (ESCI)] [Web of Science by Clarivate]

APPROVED GALLEY PROOF

Introduction

Wolff-Parkinson-White (WPW) syndrome is a congenital cardiac disorder caused by an accessory atrioventricular (AV) pathway that conducts both anterogradely and retrogradely, producing the classic triad of a shortened PR interval, delta wave, and widened QRS complex on surface ECG [1-3]. When an accessory pathway conducts exclusively in the retrograde direction—without antegrade conduction or surface ECG evidence of pre-excitation—it is classified as a concealed accessory pathway [4]. Concealed pathways can sustain orthodromic atrioventricular reentrant tachycardia (AVRT), in which impulses travel anterogradely through the AV node and retrogradely through the accessory pathway, producing a paroxysmal narrow-complex tachycardia that is electrocardiographically indistinguishable from AV nodal reentrant tachycardia on surface monitoring [4]. The prevalence of accessory pathways in the general population is estimated at 1 to 3 per 1000 individuals [5,6].

In manifest WPW syndrome—where antegrade accessory pathway conduction is demonstrated—the most serious complication is sudden cardiac death, which can occur when rapid antegrade conduction during atrial fibrillation degenerates into ventricular fibrillation [2,7]. This risk is specific to pathways with demonstrated antegrade conduction and does not apply to concealed accessory pathways, which conduct exclusively retrogradely and therefore cannot mediate this mechanism [4]. The cornerstone of management for symptomatic supraventricular arrhythmia mediated by an accessory pathway is catheter ablation, with high success rates (> 94%) and a low-risk profile [2,4].

On the opposite end of the clinical spectrum, yet with significant symptomatic overlap, lie disorders of the autonomic nervous system, collectively termed autonomic disorders. This group encompasses various conditions characterized by impaired regulation of involuntary bodily functions, including heart rate, blood pressure, and systemic perfusion [8]. These conditions can present with palpitations, syncope, dizziness, and exercise intolerance, and are generally managed through non-pharmacological measures and symptomatic pharmacological treatment, without a definitive cure [8,9]. In the patient described in this report, a specific autonomic disorder subtype was not formally established; the diagnosis was based solely on a reported positive tilt table response interpreted by the treating team.

The diagnostic challenge emerges when a patient presents with non-specific symptoms such as palpitations, syncope, presyncope, chest pain, and fatigue, which are common to both accessory pathway-mediated tachycardia and autonomic disorders [2,8]. This symptomatic overlap can create a clinical diagnostic labyrinth, in which the identification of one condition can mask the coexistence of the other. An initial focus on an autonomic disorder can delay recognition of an underlying accessory pathway tachycardia. Conversely, identification of a supraventricular tachycardia can lead to overlooking a concomitant autonomic disorder that explains persistent symptoms such as fatigue or exercise intolerance.

This case report details the complex clinical course of a young woman in whom the diagnosis of orthodromic AVRT via a concealed left-sided accessory pathway was delayed for over a decade due to symptom overlap with a reported autonomic disorder. The purpose of this report is: (1) to highlight that a concealed accessory pathway produces no surface ECG evidence of pre-excitation and may be misclassified as focal atrial tachycardia, requiring repeat electrophysiological evaluation when clinical suspicion persists; (2) to describe the diagnostic challenge when paroxysmal tachycardia coexists with a reported autonomic disorder and both share overlapping symptoms; and (3) to document that successful catheter ablation of the arrhythmic substrate can substantially improve tachycardia-related symptoms, while autonomic symptoms require separate, ongoing management.

Case Report

A 21-year-old woman with no previously established chronic diagnosis but a long-standing history of episodic tachycardia since early childhood presented for evaluation. She denied tobacco use, alcohol consumption, and recreational drug use. Written informed consent for the publication of this case was obtained from the patient and her mother.

The patient's medical follow-up began at 3 years of age due to episodes of nocturnal tachycardia that occurred without apparent fever or concomitant illness. At the age of 7, she underwent her first evaluation by a pediatric cardiologist, who made a presumptive diagnosis of tachycardia. Throughout her childhood, multiple 24-hour Holter monitor studies were conducted; however, they failed to capture any arrhythmic episodes despite the patient's continued symptoms.

At 10 years old, her symptomatology evolved. She began experiencing pain that originated in her head, progressed to the chest, and radiated to her left arm. This symptom profile prompted a first diagnostic cardiac catheterization with possible ablation, which failed to induce tachycardia. Pharmacological management was initiated between 7 and 8 years of age with propafenone and verapamil and yielded a suboptimal response, with persistence of events.

At 12 years old, she had a syncopal episode at school. Evaluation in the emergency room documented a tachycardia of 120-130

This work is licensed under Creative Commons Attribution-NonCommercial-NoDerivatives 4.0 International (CC BY-NC-ND 4.0)

Indexed in: [PMC] [PubMed] [Emerging Sources Citation Index (ESCI)] [Web of Science by Clarivate]

bpm, which resolved spontaneously. At this juncture, vasovagal syncope was considered in the differential diagnosis given its high prevalence in young individuals; however, the paroxysmal and recurrent nature of the tachycardia, its documentation at rates of 120-130 bpm, and the absence of a clear provocative trigger (such as prolonged standing, pain, or emotional distress) made a purely vasovagal mechanism less likely as the primary explanation. No formal tilt table test was performed at this stage.

At 13 years old, a second catheterization was performed, during which supraventricular tachycardia (SVT) was successfully induced; however, catheter ablation could not be performed due to a lack of supplies at the hospital. Her symptoms persisted, characterized by oppressive, burning precordial pain, headaches, left arm pain, and presyncopal episodes (near-fainting). At 14 years old, after transferring her care to a different hospital, a third catheterization was performed, without success. At 16 years old, the implantation of an insertable cardiac monitor (Reveal LINQ) was considered; however, this was not possible due to restrictions during the COVID-19 pandemic. A subsequent Holter monitor study in 2020 (Medilog Darwin Professional) documented 126 supraventricular tachycardia episodes, with a maximum heart rate of 204 bpm and the most severe episode lasting 922 seconds at 180 bpm (**Figure 1**). The initial interpretation classified the tachycardia as atrial tachycardia on surface monitoring. The patient could not be seen for follow-up at that time.

In 2023, the patient re-initiated cardiology consultation following a spontaneous syncopal episode involving loss of consciousness, accompanied by nausea, vomiting, dyspnea, and hypotension. Given the lack of success of previous interventional evaluations, the differential diagnosis was expanded to include an autonomic disorder. An exercise stress test was performed but could not be completed due to dizziness, hypotension, and near-syncope. A subsequent tilt table test was reportedly positive; however, the original protocol, beat-to-beat heart rate, blood pressure values, symptom timing, and provocation data were not available for review in this report. The specific physiologic response pattern and autonomic subtype could therefore not be independently characterized. Based on this reported result and the overall clinical picture, the treating physicians at the patient's institution recorded a clinical diagnosis of dysautonomia. Secondary causes including thyroid dysfunction, anemia, and dehydration were excluded by laboratory workup, which showed no relevant findings.

The delayed consideration of dysautonomia in this case reflects a pattern of anchoring bias: the initial clinical attention was directed exclusively toward the documented paroxysmal SVT, and dysautonomia was only incorporated into the differential after multiple failed ablation attempts. In retrospect, the coexistence of resting tachycardia, orthostatic intolerance, nausea, exercise intolerance, and exertional near-syncope—symptoms not fully explained by an accessory pathway alone—should have prompted earlier autonomic evaluation.

In 2025, following a new syncopal episode precipitated by intense chest pain, blood studies were performed, without relevant findings. A new Holter monitor was placed (**Figure 2**). The electrophysiologist's report (Dr. René Jiménez López, EEF) concluded: "Sinus rhythm conducting with a short PR of 95 ms—Atrial Tachycardia." The documented PR interval of 95 ms is below the normal lower limit of 120 ms, indicating accelerated atrioventricular conduction consistent with the presence of an accessory pathway. A total of 4261 beats (3%) were recorded at heart rates exceeding 130 bpm, with a maximum heart rate of 167 bpm. The tachycardia was initially interpreted as atrial tachycardia on surface monitoring; however, this classification was reconsidered in light of the documented short PR interval and the overall clinical picture, which raised suspicion of an accessory pathway-mediated mechanism. In orthodromic AVRT, retrograde atrial activation via the accessory pathway can produce a P wave morphology that mimics focal atrial tachycardia on surface monitoring, explaining the initial misclassification. This prompted referral for repeat electrophysiological evaluation.

On September 7, 2025, the patient underwent a new electrophysiological study with radiofrequency catheter ablation. The procedure was performed under conscious sedation with continuous monitoring. Vascular access was obtained through the right femoral vein, and diagnostic catheters were advanced under fluoroscopic guidance. Baseline conduction intervals were assessed prior to induction; the surface ECG showed no delta waves or evidence of pre-excitation at any point during the study. Tachycardia was induced using programmed ventricular stimulation. Intracardiac mapping identified a left lateral concealed accessory atrioventricular pathway conducting exclusively in the retrograde direction. Earliest retrograde atrial activation was identified at the left lateral mitral annulus using a transseptal approach. The induced tachycardia was confirmed as orthodromic AVRT, with anterograde conduction through the AV node and His-Purkinje system and retrograde conduction through the concealed left-sided accessory pathway [4,10].

Radiofrequency energy was applied at the site of earliest retrograde atrial activation, resulting in successful elimination of retrograde accessory pathway conduction. Post-ablation programmed stimulation demonstrated non-inducibility of AVRT, constituting the procedural endpoint. As no antegrade conduction had been demonstrated at any point, disappearance of pre-excitation was not applicable as an endpoint. The patient tolerated the procedure well and remained stable, with no immediate complications.

APPROVED GALLEY PROOF

This work is licensed under Creative Commons Attribution-NonCommercial-NoDerivatives 4.0 International (CC BY-NC-ND 4.0)

Indexed in: [PMC] [PubMed] [Emerging Sources Citation Index (ESCI)] [Web of Science by Clarivate]

APPROVED GALLEY PROOF

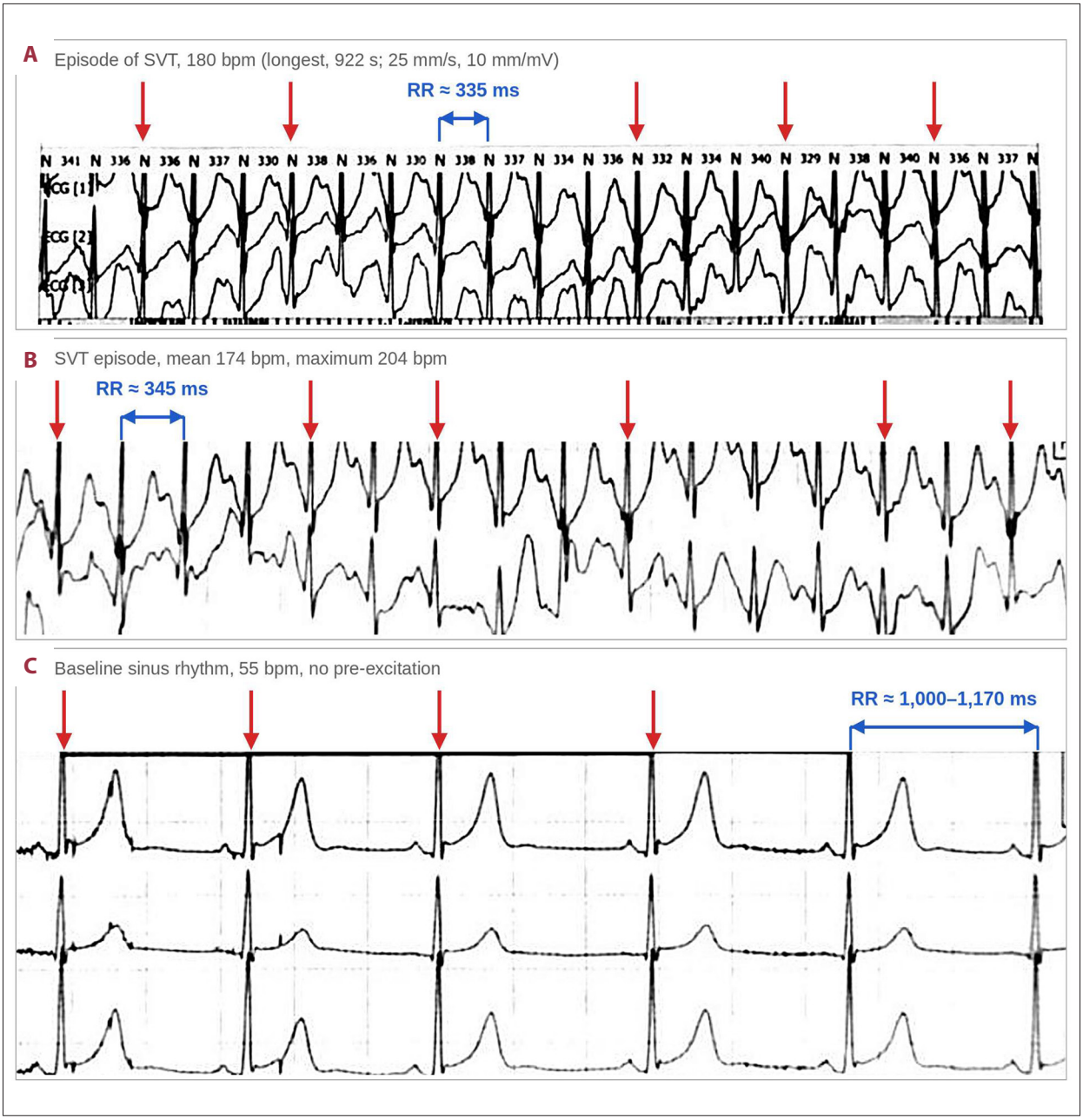

Figure 1. Holter monitor recording performed in 2020, when the patient was 16 years of age. The recording documented 126 supraventricular tachycardia (SVT) episodes, with a maximum heart rate of 204 bpm and a longest SVT episode lasting 922 seconds at 180 bpm. The referral reason was recorded in the original report as atrial tachycardia, reflecting the initial surface-level interpretation prior to electrophysiological confirmation. (**A**) Three-channel tracing of the longest SVT episode (180 bpm). (**B**) Three-channel tracing of an SVT episode with a mean rate of 174 bpm (maximum 204 bpm). Both show regular, narrow-complex tachycardia with RR intervals of approximately 335-345 ms. (**C**) Baseline sinus rhythm at 55 bpm, demonstrating normal QRS morphology without evidence of pre-excitation. Red arrows indicate QRS complexes; blue double-headed arrows indicate RR intervals. Recording speed 25 mm/s, 10 mm/mV. This study provided the first objective electrocardiographic documentation of recurrent paroxysmal SVT during this patient's prolonged diagnostic course.

This work is licensed under Creative Commons Attribution-NonCommercial-NoDerivatives 4.0 International (CC BY-NC-ND 4.0)

Indexed in: [PMC] [PubMed] [Emerging Sources Citation Index (ESCI)] [Web of Science by Clarivate]

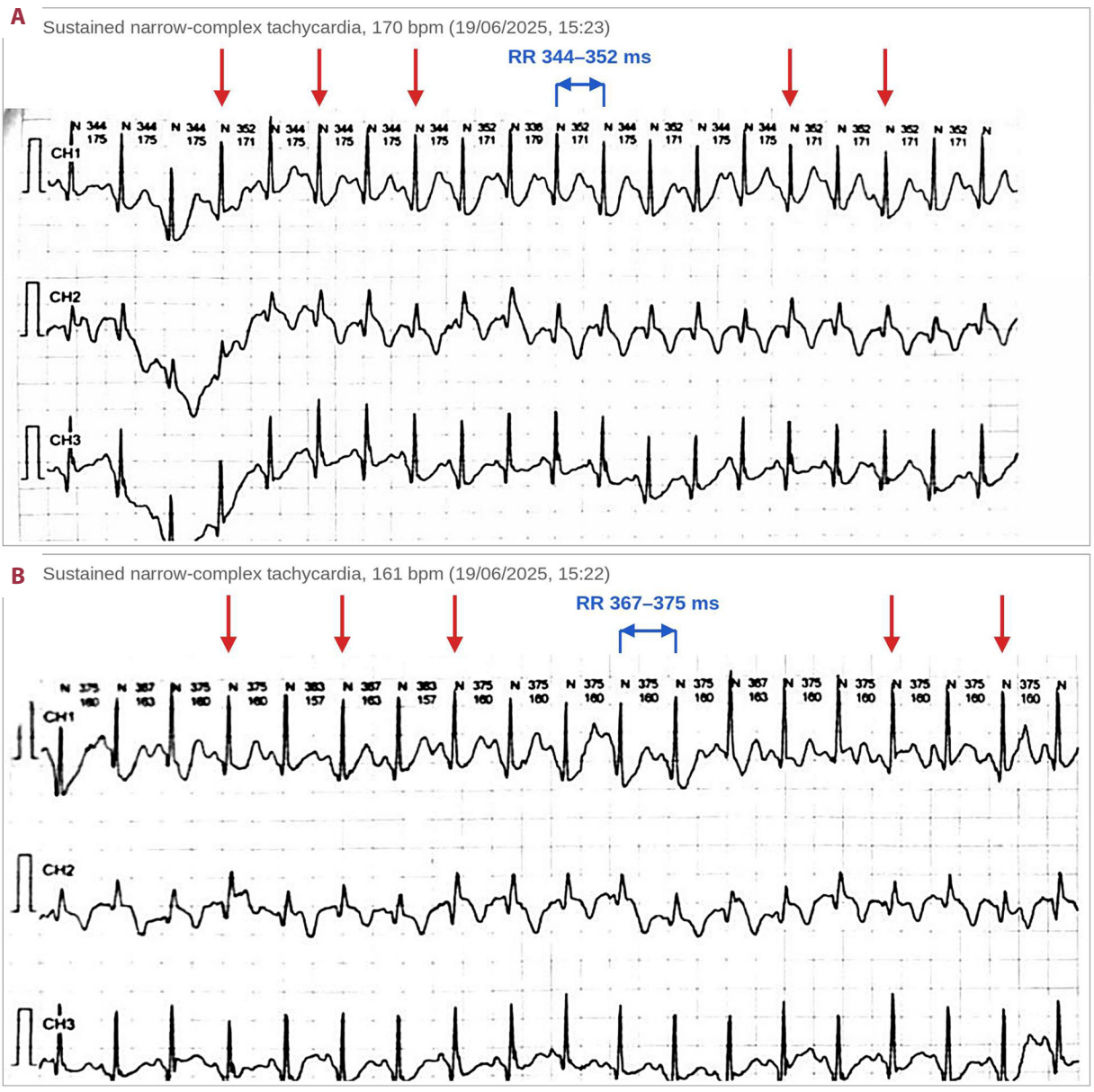

Figure 2. Holter monitor recording performed on 19 June 2025, when the patient was 21 years of age, 5 years after the 2020 recording. The electrophysiologist's report concluded: "Sinus rhythm conducting with a short PR of 95 ms—atrial tachycardia." The documented PR interval of 95 ms is below the normal lower limit of 120 ms, indicating accelerated atrioventricular conduction consistent with an accessory pathway. The recording documented 4261 beats (3%) at heart rates exceeding 130 bpm, with a maximum heart rate of 167 bpm. (**A**) Three-channel tracing at 170 bpm (19/06, 15: 23: 35) showing sustained paroxysmal narrow-complex tachycardia with regular RR intervals of 344-352 ms. (**B**) Three-channel tracing at 161 bpm (19/06, 15: 22: 36) showing an additional sustained tachycardia episode with RR intervals of 367-375 ms. Red arrows indicate QRS complexes; blue double-headed arrows indicate RR intervals. Recording speed 25 mm/s, 10 mm/mV. The initial interpretation of these recordings as atrial tachycardia on surface Holter monitoring was subsequently revised following the electrophysiological study, which confirmed orthodromic AVRT via a concealed left-sided accessory pathway. The PR shortening documented here is consistent with enhanced nodal conduction in the context of the reentrant circuit, and not with antegrade delta wave pre-excitation.

APPROVED GALLEY PROOF

This work is licensed under Creative Commons Attribution-NonCommercial-NoDerivatives 4.0 International (CC BY-NC-ND 4.0)

Indexed in: [PMC] [PubMed] [Emerging Sources Citation Index (ESCI)] [Web of Science by Clarivate]

APPROVED GALLEY PROOF



Figure 3. Twelve-lead ECG performed on September 7, 2026, 1 year after radiofrequency catheter ablation of the concealed left-sided accessory pathway. The tracing demonstrates sinus rhythm at 78 bpm, PR interval 140 ms (normal range 120-200 ms), QRS duration 82 ms, and no delta waves or evidence of ventricular pre-excitation. The report conclusion states: "Sinus rhythm, heart rate 78 bpm, electrocardiographic data within normal parameters." These findings objectively confirm successful and sustained elimination of accessory pathway conduction at one year of follow-up. Patient-identifying information has been redacted from this figure in accordance with patient privacy standards.

The post-intervention outcome was favorable with respect to the arrhythmia. The patient was informed that the clinically suspected autonomic disorder is a chronic condition requiring ongoing management. During 1 year of clinical follow-up after ablation (September 2025 to September 2026), the patient reported no recurrent episodes of sustained paroxysmal tachycardia or severe syncope. A formal 12-lead ECG was performed on September 7, 2026 (Salud Digna; validated by Dr. Leopoldo Aguila Salgado, Cardiologist, Ced. Esp. 15231555) and documented sinus rhythm at 78 bpm, PR interval 140 ms (normal), QRS duration 82 ms, and no delta waves or evidence of pre-excitation (**Figure 3**). The report concluded: "Sinus rhythm, heart rate 78 bpm, electrocardiographic data within normal parameters." This objective 12-lead ECG provides direct confirmation of successful and sustained elimination of accessory pathway conduction at 1-year follow-up. No ambulatory rhythm monitoring was performed during this period. The patient continues to experience sinus tachycardia, nausea, and intermittent symptoms, attributed by her treating physicians to the clinically suspected autonomic disorder, and she remains on bisoprolol 5 mg daily for rate control. She reports adherence to lifestyle modifications including fractionated diet, adequate hydration, and electrolyte supplementation. Diagnostic and therapeutic timelines are illustrated in **Table 1**.

Discussion

The patient's prolonged clinical course exemplifies the diagnostic challenges that arise when 2 conditions share overlapping symptomatology. This case underscores the difficulty in differentiating an accessory pathway-mediated supraventricular arrhythmia from a reported autonomic disorder. The coexistence of orthodromic AVRT via a concealed accessory pathway and a clinically suspected autonomic disorder in the same patient, while uncommon in the reported literature, is not

This work is licensed under Creative Commons Attribution-NonCommercial-NoDerivatives 4.0 International (CC BY-NC-ND 4.0)

Indexed in: [PMC] [PubMed] [Emerging Sources Citation Index (ESCI)] [Web of Science by Clarivate]

Table 1. The diagnostic and therapeutic timeline.

Age/Year	Key symptoms	Tests performed	Working diagnosis	Management
Age 3	Nocturnal tachycardia	Clinical evaluation	Undefined tachycardia	Watchful waiting
Age 7	Recurrent tachycardia	First pediatric cardiology consult; Holter (non-diagnostic)	Presumptive tachycardia	Propafenone + verapamil (ages 7–8)
Age 10	Head-to-chest-to-left arm pain	1st EP study/catheterization—non-inducible	SVT suspected	Continued antiarrhythmics
Age 12	Syncope at school, HR 120–130 bpm	ER evaluation—tachycardia documented, self-terminated	SVT	Symptomatic
Age 13	Presyncope, chest/arm pain	2nd EP study—SVT induced, ablation not performed (supply shortage)	SVT / possible accessory pathway	Continued medical therapy
Age 14	Persistent symptoms	3rd EP study—unsuccessful	Refractory SVT	Referral to different center
Age 16/ 2020	Ongoing symptoms	Holter (2020)—126 SVT episodes documented, maximum HR 204 bpm, most severe episode 922 s at 180 bpm; initial classification: atrial tachycardia (Figure 2); ICM considered but not placed (COVID-19 restrictions)	SVT	No new intervention
2023	Syncope + nausea, vomiting, dyspnea, hypotension	Exercise stress test (incomplete); Tilt Table Test—POSITIVE	Reported positive tilt table response; dysautonomia recorded as clinical diagnosis by treating team	Lifestyle modifications, hydration, salt intake
2025	Syncope + chest pain	Holter (June 2025)—PR interval 95 ms documented by electrophysiologist; tachycardia initially interpreted as atrial tachycardia on surface monitoring (Figure 3); EP study—orthodromic AVRT induced, concealed left-sided AP identified (no antegrade conduction, no delta waves on surface ECG at any point)	Orthodromic AVRT via concealed left-sided accessory pathway (concealed AP; WPW pattern not demonstrated)	Radiofrequency catheter ablation—successful (endpoint: non-inducibility of AVRT); bisoprolol 5 mg/ day for dysautonomia; follow-up ECG reported normal

APPROVED GALLEY PROOF

mechanistically linked; their co-occurrence in this case should be understood as coincidental [9]. This overlap may lead clinicians to attribute all symptoms to a single condition, delaying recognition of the other.

This patient's diagnostic journey was protracted and complex. The initial clinical focus was directed at the supraventricular arrhythmia. The prior incomplete or unsuccessful interventional evaluations—including procedures limited by non-inducibility, resource constraints, and logistical barriers—contributed to prolonged diagnostic uncertainty rather than reflecting solely a difficult-to-locate pathway [1,11]. The persistence of symptoms despite antiarrhythmic therapy was a crucial indicator that the clinical picture was incomplete.

The delayed recognition of dysautonomia in this case reflects anchoring bias: an exclusive focus on the documented SVT delayed autonomic evaluation, and dysautonomia was only considered after repeated failed interventions. Clinicians should suspect a concomitant autonomic disorder when: (a) symptoms persist between documented arrhythmic episodes; (b) orthostatic symptoms predominate; or (c) antiarrhythmic therapy provides incomplete relief.

This work is licensed under Creative Commons Attribution-NonCommercial-NoDerivatives 4.0 International (CC BY-NC-ND 4.0)

Indexed in: [PMC] [PubMed] [Emerging Sources Citation Index (ESCI)] [Web of Science by Clarivate]

APPROVED GALLEY PROOF

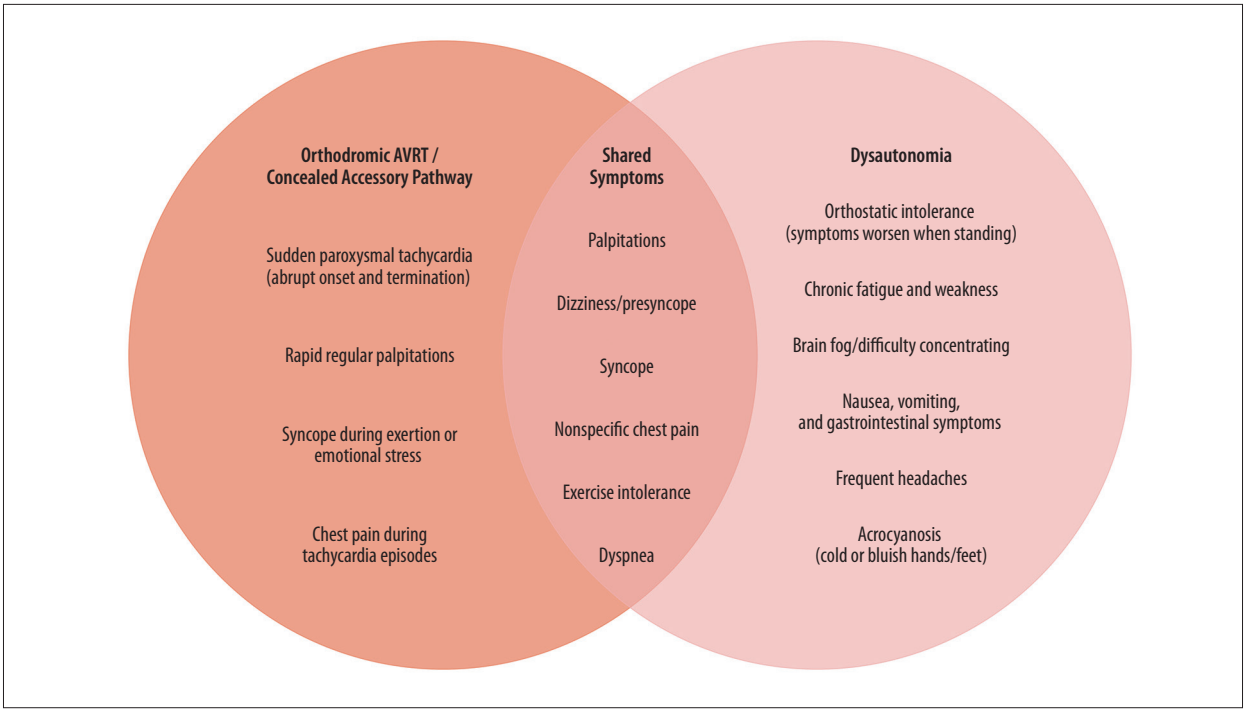

Figure 4. Venn diagram illustrating the overlap of clinical symptoms between orthodromic atrioventricular reentrant tachycardia (AVRT) via a concealed left-sided accessory pathway and Dysautonomia. The coexistence of shared manifestations such as palpitations, syncope, and exercise intolerance contributed to diagnostic complexity in this patient for several years.

The turning point in management occurred when the persistent lack of success with interventional evaluations prompted broadening of the diagnostic approach. A tilt table test was reportedly positive, which the treating physicians interpreted as supportive of an autonomic component to the patient's symptoms. The reported positive tilt table response prompted autonomic-directed management; however, the absence of the original test parameters precluded independent characterization of the response or assignment of a specific autonomic diagnosis or subtype. The specific physiologic pattern and causal relationship between the tilt response and individual symptoms could not be independently established. Unlike accessory pathway-mediated tachycardia, autonomic disorders are generally chronic conditions managed with symptom control and lifestyle adaptations, without a definitive cure [12].

In this patient, the specific subtype of autonomic disorder was not formally established beyond the reported positive tilt table response; no additional autonomic workup was performed. The tilt table test has limited specificity and can yield a positive result in conditions other than a primary autonomic disorder, including vasovagal syncope. The result should therefore be interpreted as clinically suggestive of an autonomic component rather than as confirmation of a specific diagnosis, and must be corroborated by clinical context and symptom pattern. Regardless of the specific etiology, the reported positive response and the chronic symptom burden provided the treating team with sufficient clinical grounds to initiate autonomic-directed management.

The crux of the confusion in this case was the symptomatic overlap. The patient presented with 2 concurrent conditions: orthodromic AVRT via a concealed left-sided accessory pathway, which was responsible for episodes of paroxysmal rapid tachycardia and possibly some syncopal events; and a clinically suspected autonomic disorder, which the treating team attributed to the persistent resting tachycardia, orthostatic intolerance, and gastrointestinal symptoms between arrhythmic episodes. The diagnostic confusion arose from bidirectional masking: attention to the documented SVT delayed autonomic evaluation, while the subsequently recorded autonomic disorder shifted the focus away from the persistent accessory pathway. No mechanistic association between the 2 conditions is implied or established (**Figure 4**).

A successful outcome was only achieved when both conditions were addressed in a sequential and complementary manner. Orthodromic AVRT is the most common tachyarrhythmia mediated by an accessory pathway and may occasionally be misinterpreted as focal atrial tachycardia on surface monitoring due to retrograde atrial activation [1,2]. The definitive ablation of the concealed accessory pathway in 2025 eliminated the substrate for the paroxysmal arrhythmia [1,2,4]. On the

This work is licensed under Creative Commons Attribution-NonCommercial-NoDerivatives 4.0 International (CC BY-NC-ND 4.0)

Indexed in: [PMC] [PubMed] [Emerging Sources Citation Index (ESCI)] [Web of Science by Clarivate]

other hand, the reported positive tilt table response allowed the treating team to implement autonomic-directed management—including hydration, salt intake, and lifestyle modifications—to address the chronic autonomic symptoms that, as expected, persisted despite successful ablation [12].

The following case-anchored teaching points are offered for clinical practice:

(1) Maintain dual-track evaluation: when palpitations and syncope coexist with symptoms of orthostatic intolerance or resting tachycardia, evaluate both structural arrhythmia and autonomic dysfunction in parallel rather than sequentially.
(2) Reconsider rhythm classification: AVRT can be misidentified as focal atrial tachycardia on surface ECG or Holter monitoring; subtle delta waves in sinus rhythm may be the key clue and warrant repeat electrophysiological assessment.
(3) Avoid premature diagnostic closure: failure to respond to treatment should prompt reconsideration of the diagnosis, not escalation of treatment for the assumed condition.
(4) Counsel patients on post-ablation expectations: when dysautonomia coexists, patients should be informed that autonomic symptoms—sinus tachycardia, fatigue, orthostatic intolerance—will persist after successful ablation and require separate, ongoing management.
(5) Interpret tilt table testing in the clinical context: a reported positive tilt table response should be evaluated according to the documented heart rate, blood pressure, symptom, and timing pattern; when the original hemodynamic measurements are unavailable, the result should not be used to assign a specific autonomic diagnosis or to attribute individual symptoms to autonomic dysfunction.

Conclusions

This case illustrates the diagnostic complexity that arises when orthodromic AVRT mediated by a concealed left-sided accessory pathway coexists with a clinically suspected autonomic disorder, both sharing overlapping symptomatology. The prolonged diagnostic course reflects anchoring bias and logistical barriers rather than a mechanistic interaction between the 2 conditions. Catheter ablation eliminated retrograde accessory pathway conduction, achieving non-inducibility of AVRT; at 1-year follow-up, a 12-lead ECG objectively confirmed sustained sinus rhythm with a normal PR interval and no delta waves (**Figure 3**). Symptoms attributed by the treating team to the clinically suspected autonomic disorder persisted after ablation; however, their persistence cannot independently confirm that a specific autonomic disorder was present, given the absence of independently verified hemodynamic data from the tilt table test. Each condition was managed independently based on the available clinical information. Maintaining a broad diagnostic perspective—and considering concomitant diagnoses when the clinical course is atypical or the response to treatment is incomplete—remains essential to avoid diagnostic delay and improve long-term outcomes.

Institution Where Work Was Done

Hospital Regional ISSSTE, Puebla, México.

Patient Consent

Written informed consent for publication and data privacy authorization were obtained from the patient and her mother. Patient-identifying information has been redacted from the submitted electrocardiographic figures in accordance with patient privacy standards.

Declaration of Figures' Authenticity

All figures submitted have been created by the authors who confirm that the images are original with no duplication and have not been previously published in whole or in part.

References:

1. Barat M, Barba DT, Ho G. Wolff-Parkinson-White syndrome: Diagnostic and management strategies. Cleve Clin J Med. 2025;92(2):119-27
2. Chhabra L, Goyal A, Benham MD. Wolff-Parkinson-White syndrome. 2023 Aug 7. In: StatPearls [Internet]. Treasure Island (FL): StatPearls Publishing; 2026
3. Masukume G, Dixon M. Wolff-Parkinson-White syndrome type B. Pan Afr Med J. 2022;43:177
4. Page RL, Joglar JA, Caldwell MA, et al. 2015 ACC/AHA/HRS Guideline for the management of adult patients with supraventricular tachycardia. J Am Coll Cardiol. 2016;67(13):e27-e115
5. Etheridge SP, Shah M. Top stories in Wolff-Parkinson-White syndrome (2022-2023). Heart Rhythm. 2024;21(3):357-58
6. Obeyesekere MN, Leong-Sit P, Massel D, et al. Risk of arrhythmia and sudden death in patients with asymptomatic preexcitation: A meta-analysis. Circulation. 2012;125(19):2308-15
7. Sheldon RS, Grubb BP 2nd, Olshansky B, et al. 2015 heart rhythm society expert consensus statement on the diagnosis and treatment of postural tachycardia syndrome, inappropriate sinus tachycardia, and vasovagal syncope. Heart Rhythm. 2015;12(6):e41-63
8. Bryarly M, Phillips LT, Fu Q, et al. Postural orthostatic tachycardia syndrome: JACC Focus Seminar. J Am Coll Cardiol. 2019;73(10):1207-28
9. Zhu K, Solin S, Deming MS. When zebras collide: A case of synchronous Wolff-Parkinson-White Syndrome and pheochromocytoma. Am J Case Rep. 2021;22:e934137
10. Steinberg C, Philippon F, O'Hara G, Champagne J. Orthodromic atrioventricular reentrant tachycardia using a concealed isoproterenol-sensitive accessory pathway. Indian Pacing Electrophysiol J. 2020;20(2):73-77
11. Sawasaki K, Muto M, Hosoya N. Sequential abolition of antegrade and retrograde conduction in Wolff-Parkinson-White syndrome: A case series. Am J Case Rep. 2021;22:e932381
12. Rocha EA, Mehta N, Távora-Mehta MZP, et al. Dysautonomia: A forgotten condition – Part 1. Arq Bras Cardiol. 2021;116(4):814-35

APPROVED GALLEY PROOF

This work is licensed under Creative Commons Attribution-NonCommercial-NoDerivatives 4.0 International (CC BY-NC-ND 4.0)

Indexed in: [PMC] [PubMed] [Emerging Sources Citation Index (ESCI)] [Web of Science by Clarivate]